

Juvenile Recurrent Parotitis; A Rare Case

Yakup Yegin¹, Mustafa Celik¹, Kamil Hakan Kaya¹, Burak Olgun¹, Fatma Tulin Kayhan¹

ABSTRACT:

Juvenile recurrent parotitis; a rare case

Introduction: Juvenile recurrent parotitis (JRP) is a nonspecific, nonobstructive, nonsuppurative disease that is characterized by intermittent swelling of one or both parotid glands in children. The etiology is unknown but autoimmunity, ductal obstruction, immune deficiency, and infectious causes have all been proposed. The diagnosis is suggested from the history of the disease, the clinical examination and radiological findings. Several treatment modality is proposed. The first line of treatment consists of conservative observation such as antibiotics, analgesics.

Case Report: Herein, we report a 11-years old child patient with recurrent acute parotitis with the evaluation of the etiology of disease and review the relevant literature.

Conclusion: JRP should be considered in the differential diagnosis of patients with acute recurrent parotitis swelling. A high degree of clinical suspicion is needed to determine this rare potential etiology.

Key words: Child, juvenile recurrent parotitis, salivary gland

ÖZET:

Jüvenil rekürren parotit; Nadir bir olgu

Giriş: Jüvenil rekürren parotit (JRP), çocuklarda görülen parotis bezinin tek veya iki taraflı şişmesiyle karakterize, ataklar şeklinde seyreden, spesifik, tıkaçıcı ve süpüratif olmayan inflamatuvar hastalıdır. Etyolojisi bilinmemekle beraber otoimmünite, duktal obstrüksiyon, immün yetmezlik ve enfeksiyöz nedenler suçlanmaktadır. Tanısı anamnez, fizik muayene ve radyolojik bulgularla konulur. Birçok tedavi modalitesi önerilmiştir. İlk basamak tedavisi antibiyotikler, analjezikler gibi konservatif tedavidir.

Olgu Sunumu: Bu makalede kliniğimizde tekrarlayan akut parotit nedeniyle takip edilen ve etyolojisi araştırılan 11 yaşında çocuk hasta güncel literatür bilgileri ışığında sunuldu.

Sonuç: JRP tekrarlayan akut parotitis bezi şişliklerinin ayırıcı tanısında düşünülmelidir. Nadir etyolojilerin saptanmasında klinik şüphe oldukça önemlidir.

Anahtar kelimeler: Çocuk, jüvenil rekürren parotit, tükürük bezi

Ş.E.E.A.H. Tıp Bülteni 2016;50(3):237-40



*Bakirkoy Dr. Sadi Konuk Training and Research Hospital, Department of Otolaryngology Head and Neck Surgery, Istanbul - Turkey

Address reprint requests to / Yazışma Adresi: Mustafa Celik, Bakirkoy Dr. Sadi Konuk Training and Research Hospital, Department of Otolaryngology Head and Neck Surgery, Istanbul - Turkey

E-mail / E-posta: dr.mcelik@yahoo.com

Date of receipt / Geliş tarihi: July 22, 2015 / 22 Temmuz 2015

Date of acceptance / Kabul tarihi: October 11, 2015 / 11 Ekim 2015

INTRODUCTION

Juvenile recurrent parotitis (JRP) is a nonspecific, nonobstructive, nonsuppurative disease that is characterized by intermittent swelling of one or both parotid glands in children (1). It is the second most common infection of the parotid gland in children following paramyxovirus (mumps) infection. Mumps accounts for the approximately 98% of the pediatric cases, while the incidence of JRP is reported to be between 1.1% and 1.9% (2,3). In the literature, there are only 69 articles related with non-mumps-induced pediatric parotitis (1985-2015). Current literature

indicates that even though it is rare, it should be necessarily considered in the differential diagnosis of parotitis. However, Due to its rarity, the diagnosis is usually made lately (1). In this article, the diagnosis, treatment and follow-up phases of a 11-year-old case with recurrent parotitis was presented in the light of the current literature.

CASE REPORT

An 11-year-old male patient was admitted to our clinic with a swelling, redness, pain on the right parotitis region for the last 3 days. The patient's

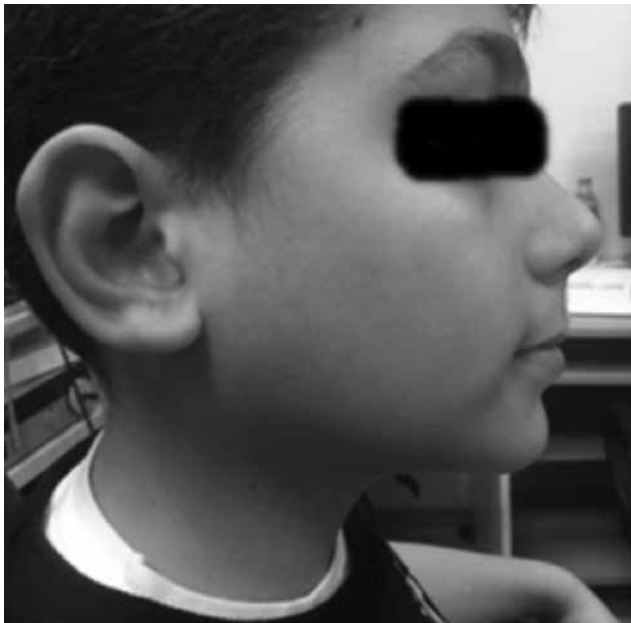


Figure-1: Swelling on the right parotid gland (5th day of treatment of the acute attack; hyperemia and temperature increase regressed, but swelling continues).

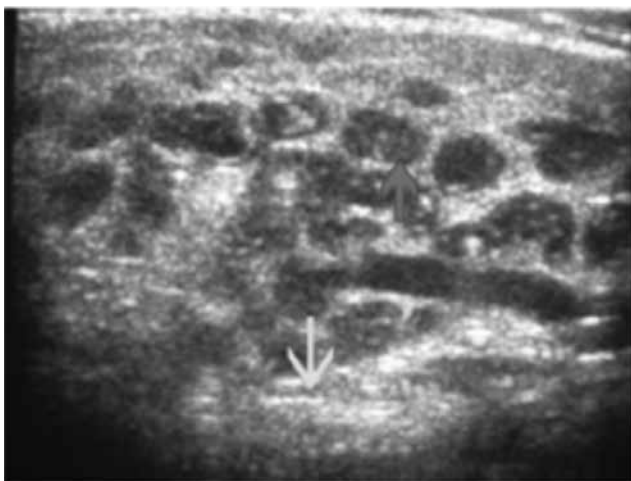


Figure-2: USG image; many hypoechoic areas at the right parotid gland (red arrow), hyperechoic calcifications (green arrow).⁷

history revealed that the patient was diagnosed as mumps for the similar complaints before, but despite the reduction of the complaints of the patient with treatment, they repeated more than 5 times a year. It was learned from his family that during each attack, the same area was being affected and there was no

accompanying systemic symptom such as the mouth and eye dryness, skin rash and joint pain. In the physical examination of the patient without an unknown drug and food allergy, a firm, fixed, painful mass of 3x2 cm size with redness on the surface at the right parotid region was detected (Figure-1). The other ear, nose and throat and systemic examinations of the patient were unremarkable. In the laboratory examination, the WBC count was 14,750/mm³ (85% neutrophil domination), the erythrocyte sedimentation rate was 39 mm/hour, turbidimetric C-reactive protein (CRP) was 3.6 mg/dl. The other biochemical tests were within normal limits. At the neck ultrasonography (USG), the right parotid was larger than the left one, and there were numerous hypoechoic areas, hyperechoic calcifications at the right parotid gland, and Stensen duct was wider on the right side, with no signs of obstruction (Figure-2). Amoxicillin-clavulanate (40 mg/kg/day) and analgesic therapy were given for 2 weeks due to acute parotitis, and the patient was taken under investigation for the etiology of recurrent parotitis. At the investigation of the immune deficiency, the immunoglobulins were within normal limits for age, rheumatoid factor (RF), antinuclear antibody, anti-deoxyribonucleic acid, anti-SSA, anti-SSB antibodies have been found to be negative. The ophthalmologic examination performed in the eye clinic for the exclusion of dry eye and autoimmune uveitis was defined as normal. Buccal salivary gland biopsy for the exclusion of Sjögren's syndrome was performed under local anesthesia and the pathological examination result was reported to be normal. No computed tomography (CT) was performed, with the side effects of the radiation kept in mind. Sialendoscopic examination couldn't be performed because we had no unit for sialendoscopy. The patient was monitored in our clinic with JRP diagnosis and in his 1-year follow-up, it was seen that his complaints repeated for 7 times and regressed in 2 weeks with symptomatic treatment each time. The patient was recommended the tying of Stensen's channel, tympanic neurectomy, superficial and total parotidectomy operations, with explaining the risks, but the family stated they they didn't accept the surgical intervention.

Informed consent: Informed consent from the

family of the patient present in this study and permission for publication were taken.

DISCUSSION

Juvenile recurrent parotitis (JRP) is an inflammatory disease that is characterized by intermittent swelling of one or both parotid glands (1). It is often a self-limiting disease, with the diagnosis making its peak mostly between the ages of 3-6 (4). The disease is more often in the male sex, with a dominance in girls after the period of puberty (5). The frequency of the recurrences is variable, with cases seen with more than 10 attacks per year reported (1,3). The children are generally asymptomatic between the recurrence periods and the periods between the recurrences vary from patient to patient (6).

The disease is unilateral in most cases (66%), however, bilateral cases have also been reported (1,4). When bilateral, symptoms on one side are dominantly clinical (1). Symptoms are as pain, swelling, redness and temperature increase at the affected side, and are usually accompanied by generally systematic fever (3). The first attack typically occurs at age of 1-2, but is delayed due to the misdiagnosis such as mumps, otitis or pharyngitis (1). However, the recurrent infections of the parotid gland which is bigger than normal, may be mixed with JRP. In the differential diagnosis, Godwin's benign lymphoepithelial lesions, sialadenitis, tuberculosis, sarcoidosis, pneumoparotitis, chronic punctate sialadenitis, Mikulicz disease and Sjögren's syndrome should be considered (1,2).

The etiology of JRP is not fully known, but some factors have been suggested to play a role in the etiology (3,5). Congenital malformations, genetics, primary or secondary infections, allergy, systemic immunological diseases and malocclusion are the factors that are charged (1,3,6). Reid et al. (7) in a genetic study they performed in a family with recurrent parotitis, reported that JRP is disease with an autosomal dominant trait. Fazekas et al. (8) reported that selective IgA deficiency to be more common in children with JRP, compared to healthy children. Systemic and local immune deficiency have been suggested to play a role in the etiopathogenesis (1,5). JRP has also been

suggested to be the first indicator in Sjögren's syndrome (9). Allergy is also a factor that is implicated but cannot be proved in the etiopathogenesis (1). The USG in this case showed no evidence of a finding of congenital malformation or ductal obstruction; the immunological tests showed no immune deficiency and the patient had no anamnesis of a known allergy. Even though different theories have been proposed in the literature, the prevailing opinion today is that it is a multifactorial disease (1,5). However, the main cause of the disease is thought as the ascending progression of infectious agents in the oral cavity to the salivary glands, and cause a reduction in the production of the saliva by causing an insufficient saliva in the ductal system (1). The partial obstruction of the ductal system results with retention and ductal dilatation. The resulting sialoectasis then leads up to recurrent infections (1).

JRP is generally diagnosed with the history, physical examination and imaging techniques after the third or fourth attack (2,3). The periods between the attacks are variable, and may range from 15 days to 2 months. The frequency of attacks is an important factor that also determines the severity of the disease. But the real severity of the disease is the progression of the irreversible damage of the parenchyme which reduces the gland's functions more than 50% (1). Unlike other pathologies of the parotid, fine needle aspiration biopsy (FNAB) has no indication in the diagnosis. Unnecessary FNAB is generally performed in cases where the pathologies of the parotid are not remembered in the differential diagnosis in cases of JRP (6). USG is the preferred method of imaging, where CT, MRI, sialography and MRI- sialography are also the radiological tests that can be used (10,11). Sialendoscopy is also a radiological test that is used for both diagnosis and treatment recently (11). In the USG, hypoechoic areas, ponds, ductal dilatation and a wide-open ostium in the parotid gland are detected (1). In our case, CT was not performed, considering the side effects of the radiation. The patient was monitored with USG. Our patient's USG findings were consistent with JRP.

JRP treatment modalities range from conservative treatment approaches to invasive surgical procedures. Many authors report no use of antibiotics during the

attack, while others report no effect of prophylactic antibiotics on progression (4,6). However Cohen et al. (12) stated that long-term prophylactic low-dose antibiotherapy should be used in children with IgA deficiency. Antibiotherapy, fluid intake, oral care, gum chewing and sialogogues are recommended as the first-line therapy (1,4,6). The tying of Stensen's channel, tympanic neurectomy, superficial or total parotidectomy are the treatment choices in cases with more severe clinics (10,11). The tying of Stensen's channel causes atrophy in secretory acinar cells due to the pressure. However, it is rarely applied due to the occurrence of frequent sialoceles and abscess. The unsatisfactory results of tympanic neurectomy which is another method that causes acinar cell atrophy cause to a limited application of the tympanic neurectomy (4,6). Although parotidectomy is thought to be a last treatment option for JRP, it is reported that the symptoms regress completely with total parotidectomy, but with superficial parotidectomy, not completely (11). Although there is not a clear study in the literature, related with the success rate of total parotidectomy and superficial parotidectomy in the treatment of JRP, by Moody et al. (13), Orvidas et al. (14) and Laskawi et al. (15), the complaints were reported to regress completely with the total excision of the parotis gland

(11). Lavage is performed with substances such as iodine injected intraductally in sialography, cortisone and methyl violet. Katz et al. (1) reported that in cases with JRP, the symptoms regress with sialography with iodine during the 1-year follow-up, and didn't repeat. Sialoendoscopy is a new method performed under local or general anesthesia with a semi-rigid mini-endoscope. It is a minimally invasive, safe and effective method. The most frequent pathology in sialoendoscopy is the white, avascular appearance of the mucosa of the channel (5,10). The place of sialoendoscopy in the treatment of JRP is the washing of mucosal debris with a fluid such as corticosteroid and the opening of the strictures (5). Although sialography and sialoendoscopy are the recently featured new treatment options, there are no adequate studies on long-term results.

There is no literature about whether JRP is a malignant disease or not. Long-term follow-up will provide enlightenment in this dark spot.

CONCLUSION

Although JRP is rare in childhood, it should be considered in the differential diagnosis with recurrent acute parotitis clinic. The monitoring of the patients will allow us to gain more experience about the disease.

REFERENCES

- Katz P, Hartl DM, Guerre A. Treatment of juvenile recurrent parotitis. *Otolaryngol Clin N Am* 2009; 42: 1087-91. [CrossRef]
- Nahielli O, Bar T, Shacham R, Eliav E, Hecht-Nakar L. Management of chronic recurrent parotitis: current therapy. *J Oral Maxillofac Surg* 2004; 62: 1150-5. [CrossRef]
- Quenin S, Plouin-Gaudon I, Marchal F, Froehlich P, Disant F, Faure F. Juvenile recurrent parotitis. *Arch Otolaryngol Head Neck Surg* 2008; 134: 715-9. [CrossRef]
- Roby BB, Mattingly J, Jensen EL, Gao D, Chan KH. Treatment of juvenile recurrent parotitis of childhood. *JAMA Otolaryngol Head Neck Surg* 2015; 141: 126-9. [CrossRef]
- Ramakrishna J, Strychowsky J, Gupta M, Sommer DD. Sialendoscopy for the management of juvenile recurrent parotitis: A systematic review and meta-analysis. *Laryngoscope* 2015; 125: 1472-9. [CrossRef]
- Capaccio P, Sigismund PE, Luca N, Marchisio P, Pignataro L. Modern management of juvenile recurrent parotitis. *J Laryngol Otol*. 2012; 126: 1254-60. [CrossRef]
- Reid E, Douglas F, Crow Y, Hollman A, Gibson J. Autosomal dominant juvenile recurrent parotitis. *J Med Genet* 1998; 35: 417-9. [CrossRef]
- Fazekas T, Wiesbauer P, Schroth B, Pötschger U, Gadner H, Heitger A. Selective IgA deficiency in children with recurrent parotitis of childhood. *Pediatr Infect Dis J* 2005; 24: 461-2. [CrossRef]
- Shkalim V, Monselise Y, Mosseri R, Finkelstein Y, Garty BZ. Recurrent parotitis in selective IgA deficiency. *Pediatr Allergy Immunol* 2004; 15: 281-3. [CrossRef]
- Gadodia A, Seith A, Sharma R, Thakar A. MRI and MR sialography of juvenile recurrent parotitis. *Pediatr Radiol* 2010; 40: 1405-10. [CrossRef]
- Mikolajczak S, Meyer MF, Beutner D, Luers JC. Treatment of chronic recurrent juvenile parotitis using sialoendoscopy. *Acta Otolaryngol* 2014; 134: 531-5. [CrossRef]
- Cohen HA, Gross S, Nussinovitch M, Frydman M, Varsano I. Recurrent parotitis. *Arch Dis Child* 1992; 67: 1036-7. [CrossRef]
- Moody AB, Avery CM, Walsh S, Sneddon K, Langdon JD. Surgical management of chronic parotid disease. *Br J Oral Maxillofac Surg* 2000; 38: 620-2. [CrossRef]
- Orvidas LJ, Kasperbauer JL, Lewis JE, Olsen KD, Lesnick TG. Pediatric parotid masses. *Arch Otolaryngol Head Neck Surg* 2000; 126: 177-84. [CrossRef]
- Laskawi R, Schaffranietz F, Arglebe C, Ellies M. Inflammatory diseases of the salivary glands in infants and adolescents. *Int J Pediatr Otorhinolaryngol* 2006; 70: 129-36. [CrossRef]