

PROFESSIONAL PAPER

doi: 10.5455/medarch.2020.74.216-223

MED ARCH. 2020 JUN; 74(3): 216-223

RECEIVED: APR 02, 2020 | ACCEPTED: JUN 05, 2020

¹Digestive Surgery Department, 108 Military Central Hospital, Hanoi, Vietnam

²Department of Radiology, Pham Ngoc Thach University of Medicine, Ho Chi Minh City, Vietnam

³Department of Radiology, Viet Duc Hospital, Hanoi, Vietnam

⁴General Surgery Department, 105 Military Hospital, Hanoi, Viet Nam

Corresponding author: Nguyen Minh Duc, MD. Department of Radiology, Pham Ngoc Thach University of Medicine, 02 Duong Quang Trung Ward 12 District 10, Ho Chi Minh City, Vietnam. E-mail: bsnguyenminhduc@pnt.edu.vn, Orcid ID: <https://orcid.org/0000-0001-5411-1492>.

The Efficacy of Transanal Total Mesorectal Excision: a Preliminary Vietnamese Report

Nguyen Anh Tuan¹, Nguyen Minh Duc², Pham Van Hiep¹, Than Van Sy³, Nguyen Van Du¹, Ngo Tien Khuong⁴

ABSTRACT

Introduction: The physical anatomical characteristics of Vietnamese people are similar to those of other East Asian populations, with a deep and narrow pelvis but an average body mass index (BMI) among patients at the advanced stage of rectal cancer. **Aim:** This study aimed to prospectively evaluate the short-term outcomes of transanal total mesorectal excision (TaTME) for rectal cancer treatment in a Vietnamese population. **Methods:** A total of 64 patients who underwent TaTME were included in this study. The pelvic anatomical parameters, BMI, operative morbidities, macroscopic qualities of the mesorectal specimens, circumferential resection margins, and anal sphincter functional data were collected. The method popularized by Quirke and Kirwan's classification were used to assess to quality of the mesorectal specimens and the sphincter function, respectively. Statistical analysis was performed using SPSS 20.0. **Results:** The mean age and BMI of the patients were 66.4 years and 20.5 kg/m², respectively. Most patients had narrow pelvises, with mean transverse pelvic outlet diameters of 10.12 ± 1.85 cm, for males, and 10.43 ± 1.32 cm, for females, and pelvic depths of 12.36 ± 2.03 cm, for males, and 11.73 ± 1.12 cm, for females. The mean tumor size was 5.17 ± 1.62 cm. Among the mesorectal specimens, 82.8% were complete and 14.1% were nearly complete. Disease-free survival and overall survival rates were 98.2% and 100%, respectively. Sphincter functions at 12 months post-operation were rated as 30.8% Kirwan I, 42.3% Kirwan II, and 26.9% Kirwan III. **Conclusion:** TaTME surgery represents a safe and suitable option among Vietnamese patients with narrow and deep pelvises and advanced rectal tumors in the middle third and lower third of the rectum.

Keywords: Transanal Total Mesorectal Excision, Rectal Cancer, Consecutive Patients, Vietnam.

1. INTRODUCTION

Rectal cancer is the third-most deadly and fourth-most commonly diagnosed cancer in the world (1). Multi-modal treatment, combined with pre-operative radiotherapy and total mesorectal excision (TME) surgery, can significantly improve local recurrence and survival rates. The conventional top-down approach has been associated with difficulties and dissatisfactory outcomes, both in terms of oncological results and the ability to preserve sphincter function, especially when tumors occur in the middle and lower thirds of the rectum, in male patients with narrow pelvises, in patients with obesity, and when the tumor size is large or requires postoperative radiotherapy. The COLOR II study identified the three primary reasons for laparoscopic to open surgical conversion to be a narrow pelvis (22%), obesity (10%), and fixed tumors (9%)(2).

In 2013, a study by Sylla et al. demonstrated the advantages of a new cancer surgery approach, known as transanal total mesorectal excision (TaTME), during which two access lines from the bottom of the anus (down-to-top) are combined with the top-down approach, which may represent a new solution for overcoming the limitations associated with conventional TME surgery (3). In recent years, many studies have demonstrated this technique to be feasible and safe, increasing the rate of complete mesorectal excision and the ability to preserve the sphincter. However, some studies have suggested that this method is primarily beneficial in cases associated with a narrow pelvis, large tumors, and obesity (4).

The physical anatomical characteristics of the Vietnamese people are similar to those of other East Asian populations, with a deep and narrow pelvis

© 2020 Nguyen Anh Tuan, Nguyen Minh Duc, Pham Van Hiep, Than Van Sy, Nguyen Van Du, Ngo Tien Khuong

This is an Open Access article distributed under the terms of the Creative Commons Attribution Non-Commercial License (<http://creativecommons.org/licenses/by-nc/4.0/>) which permits unrestricted non-commercial use, distribution, and reproduction in any medium, provided the original work is properly cited.

(5, 6). Even among female patients, obesity is rare; however, large tumors, which are identified in most cases, are the primary causes of late diagnosis (7). We sought to determine whether TaTME surgery could benefit these patients. The research team at 108 Military Central Hospital is the first group in Vietnam to apply the TaTME surgical technique.

2. AIM

This study aims to evaluate the early results of TaTME surgery for the treatment of middle- and lower-third rectal cancer in Vietnamese patients with average BMIs and narrow pelvises.

3. MATERIAL AND METHODS

The study was approved by the Ethics Committee of 108 Military Central Hospital (Ref: 786/QĐ-BV, dated 08 March 2018). Every patient signed an informed consent form before inclusion in the study.

Subjects

A total of 64 consecutive patients, with middle or low rectal cancer, who underwent laparoscopic TaTME in the Digestive Surgery Department, 108 Military Central Hospital, Hanoi, Vietnam, from July 2017 to July 2019, were enrolled in this study. Rectal cancer was diagnosed based on the results of colonoscopy, biopsy, 3.0 Tesla magnetic resonance imaging (MRI, Discovery 3.0 Tesla MR750, GE Healthcare, US), and computed tomography (CT, Brivo 385, with 16 slices, GE Healthcare, US).

Neoadjuvant chemoradiation was performed in all patients with T3-T4N0 or T1-T4,N+ tumors, according to the preoperative staging guidelines. The protocol included a total dose of 50.4 Gy, with a daily dose of 1.8 Gy, administered five days each week, and chemotherapy was administered, in the form of a continuous capecitabine infusion at 225 mg/m²/day, five days each week, concomitant with radiation therapy.

Patients were re-examined at 1 month, 3 months, 6 months, and 9 months after surgery. Postoperative complications, including bleeding, anastomosis leakage, sphincter function, recurrence, and metastasis were detected through clinical examinations and CT and MRI scans.

Tumor characteristics and staging

The staging and classification of the tumor were performed before the neoadjuvant treatment, by performing CT scans of the chest, abdomen, and pelvis, endorectal ultrasound, and pelvic MRI. The tumor was reclassified after surgery, according to the 7th American Joint Committee on Cancer (AJCC) classification (8). A pelvic MRI was used to measure tumor heights and to predict the circumferential resection margin (CRM), which was defined as the shortest distance between the rectal tumor and the mesorectal fascia.

Pelvic anatomical parameters

Pelvic anatomical parameters were recorded. The anteroposterior diameter of the pelvic inlet was defined as the distance between the superior aspect of the pubis symphysis and the sacral promontory; the transverse diameter of the pelvic inlet was defined as the longest

lateral axis in the iliopectineal line; the anteroposterior diameter of the pelvic outlet was defined as the distance from the inferior aspect of the pubis symphysis to the tip of the coccyx; the transverse diameter of the pelvic outlet was defined as the distance between the tips of the ischial spines; and the pelvic depth was defined as the distance between the sacral promontory and the tip of the coccyx.

Surgical procedures

A standardized surgical procedure was performed, by a team of experienced rectal surgeons. Patients were placed in the Lloyd Davies position. Abdominal laparoscopy was performed to assess distant metastasis or peritoneal dissemination. The TaTME procedure commenced with the perineal phase. The rectum was irrigated with an iodine solution, and a Lone Star Retractor System (Cooper Surgical Inc., Trumbull, Connecticut, USA) was used. For tumors located within 1 cm of the anal verge, a hand-sewn purse-string around the anus was performed (Figure 1A). The plane dissection was extended cranially, up between the intersphincteric space, to the level of the puborectal sling (Figure 1B).

For higher tumors, rectums were occluded below

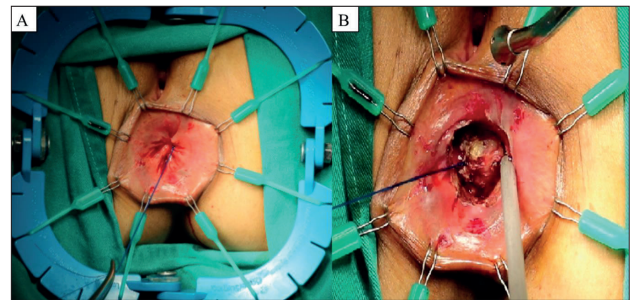


Figure 1. (A) Purse-string was made, 1 cm from the tumor edge. (B) The initial resection.

the tumor with an endoluminal purse-string. The GelPOINT PathTransanal Access Platform (Applied Medical, Inc., Rancho Santa Margarita, California, USA) was inserted, providing three airtight access channels (two 5-mm channels and one 10-mm channel) and an air inlet tube. The pelvic cavity was insufflated with CO₂, to a pressure of 10–12 mmHg. After the full thickness circumferential division of the rectal wall, the ‘holy’ plane was identified posteriorly, in the 5 or 7 o’clock position, allowing the initial dissection in the posterior plane, before being extended to the lateral and anterior aspects (Figure 2). Finally, the rectovaginal peritoneal reflection was identified, and a break-through was performed to enter the peritoneal cavity (Figure 3).

At the abdominal phase, we used a 30-degree scope at the umbilicus, with 10-mm, 12-mm, and 5-mm ports at the lower right quadrant and a 5-mm port at the lower left quadrant. In some cases, a fifth suprapubic port was used to lift the uterus. After the division of the inferior mesenteric artery and vein, the left colon was completely mobilized and the splenic flexure was mobilized. TME was performed top-down, along the avascular space, preserving the autonomic nerve plexus. In all cases, the specimen was extracted transanally and the proximal margin was marked and divided (Figure 4A). The length

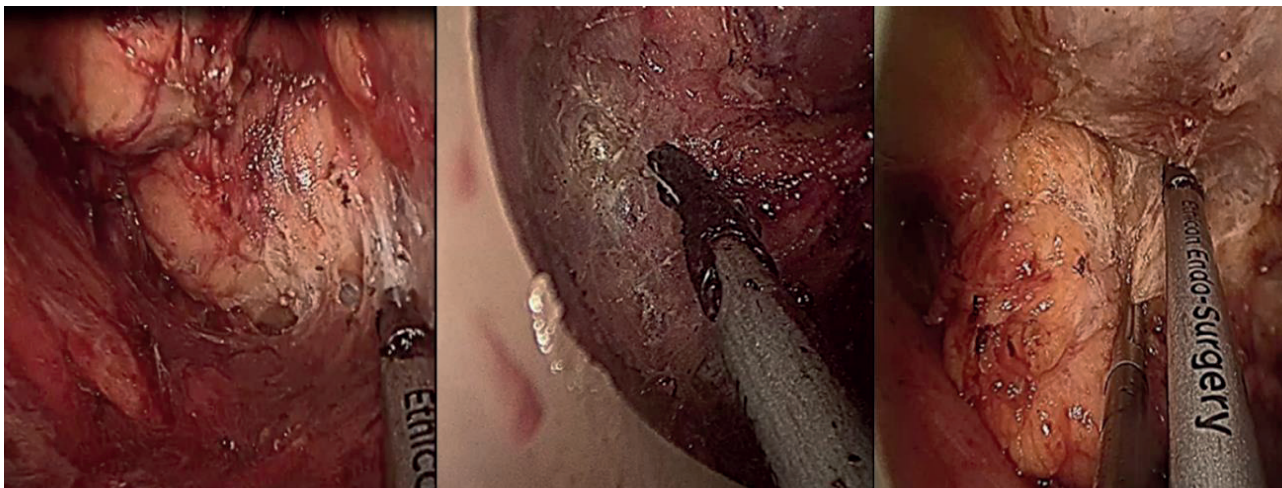


Figure 2. The down-to-top dissection along the avascular plane.

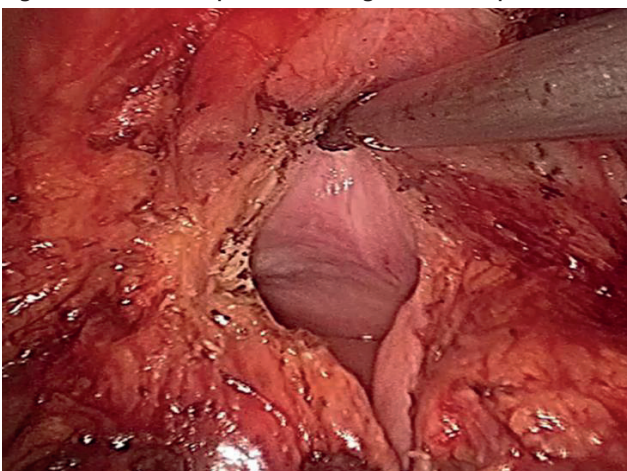


Figure 3. The perineal phase stopped when the rectovaginal peritoneal reflection was identified.

operative complications were defined and recorded as complications occurring within 30 days after surgery and were categorized according to the Clavien-Dindo classification (9). Late postoperative complications were defined as any complication occurring more than 30 days after the operation (9). Anastomotic leakage was defined according to the International Study Group of Rectal Cancer (ISGRC) classification (10), which grades severity based on the impacts on patients' clinical management.

The quality of the mesorectum excision was assessed by the surgeon in the operative room and by the pathologist, according to the grading described by Quirke and colleagues (11). The quality of the mesorectum includes three grades. (1) Complete: intact mesorectum, with only minor irregularities of a smooth mesorectal surface. No defect is deeper than 5 mm, and no coning is

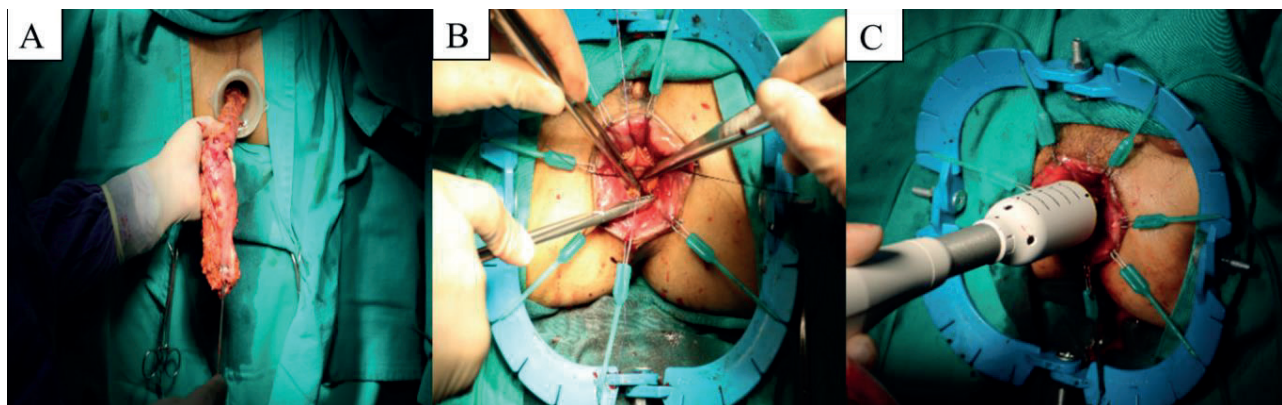


Figure 4. Transanal withdrawal of the specimen (A). Handsewn (B) and stapled anastomosis (C)

of the remaining colon was carefully evaluated, to prevent tension and poor perfusion. Hand-sewn coloanal anastomosis was performed for patients with low rectal tumors (Figure 4B), whereas in those with middle rectal cancer, stapled anastomosis was performed (Figure 4C). A protective ileostomy in the right lower quadrant was performed, in some initial cases. A suction drain was placed in the deep pelvis.

Conversion is defined as a laparoscopic case that must be converted to open surgery because of the development of a complication that cannot be adequately managed using the laparoscopic technique. Early post-

observed toward the distal margin of the specimen. The CRM is smooth on slicing (2). Nearly complete: moderate bulk to the mesorectum but irregularity of the mesorectal surface. Moderate coning of the specimen is allowed. At no site is the muscularis propria visible, except for the insertion of the levator muscles (3). Incomplete: little bulk to mesorectum. Defects in the mesorectum, down to the muscularis propria. Very irregular CRM on slicing of specimens with pronounced coning.

CRM involvement was defined as the presence of tumor cells located ≤ 1 mm from the circumferential margin, on histopathological assessment (11). The proximal

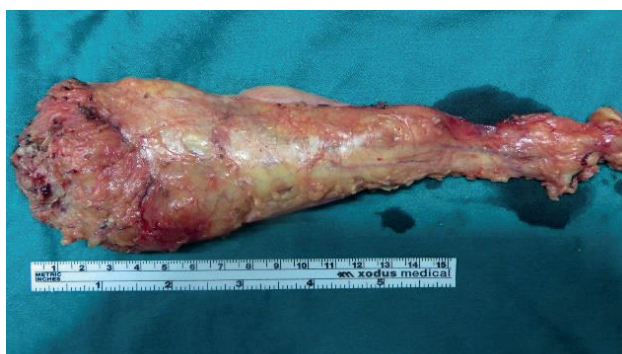

Figure 5. Specimens were examined by the pathologist

margin resection was defined as the distance from the sigmoid resection margin to the upper edge of the tumor, and the distal resection margin was defined as the distance from the lower edge of the tumor to the rectal resection margin. Fecal incontinence was evaluated using Kirwan's classification (12).

Statistical analysis

All data were analyzed using SPSS version 20.0 (IBM corp., New York, USA). The results are presented as the mean and standard deviation. The chi-squared test was used to evaluate categorical variables. Student's t-test was used for normally distributed quantitative data. Statistical significance was set at $P < 0.05$.

4. RESULTS

Patients' characteristics

A total of 64 patients, with middle and lower rectal cancer, treated using TaTME, were included in the study (Table 1). Laparoscopic procedures were performed in all patients (100%). The mean BMI was 20.5 ± 2.6 (16-27). The majority of patients were male (67.2%). The mean distance from the tumor to the anal verge was 4.7 ± 1.8 cm. On pretreatment MRI, the majority of patients (73.4%) had T3 tumors and positive lymph nodes (75%).

Perioperative outcomes

As shown in Table 3, 64 (100%) patients underwent laparoscopic TME. The specimen was extracted transanally, in all cases. Most patients received a hand-sewn, coloanal anastomosis (79.7%). Two patients experienced intraoperative complications (3.2%), with one case involving pelvic bleeding from the posterior side of the prostate and one case experiencing a rectal perforation during the transanal dissection. No conversions were necessary, and no perioperative mortality was recorded. Overall, 15 patients (23.4%) experienced postoperative complications, with most being associated with urinary retention. Most of these patients (17.3%) were classified Clavien-Dindo Grade I or II, and three patients (4.8%) experienced major complications (Clavien-Dindo Grade IIIb), which required reoperation: one anastomosis leakage, one rectovaginal leakage, and one anastomosis-combined stenosis and leakage, which required a permanent transverse colostomy. One patient who experienced anastomotic leakage was treated with transanal reinforcing stitches.

Histopathological results

Pathological data are reported in Table 4. A complete TME specimen was removed from 53 patients (82.8%). Most patients had a pT2 or a pT3 tumor (84.3%). The mean distal margin was 2.37 ± 0.75 cm, and none of the distal margins were positive. The mean proximal margin was 13.27 ± 6.94 cm. The CRM positivity rate was 4.8%.

Oncological outcomes

As shown in Table 5, the mean follow-up time was 10.0 ± 3.9 months. One patient experienced simultaneous local recurrence and dissemination in the abdomen, six months after the initial surgery, which required chemotherapy. No port-site recurrences were reported. At the end of follow-up, no patients had died.

Functional outcomes

The sphincter function was monitored and assessed monthly, based on Kirwan's classification, in patients

Characteristic	Data
Age, years, mean \pm SD (range)	66.4 \pm 11.7 (45-86)
Sex, n (%)	Male 43 (67.2)
	Female 21 (32.8)
ASA score, n (%)	I 8 (12.5)
	II 42 (65.7)
	III 14 (21.9)
Previous abdominal open surgery, n (%)	9 (14)
Tumor location, n (%)	Middle rectum 38 (59.4)
	Lower rectum 26 (40.6)
Distance from anal verge by MRI, cm, mean \pm SD (range)	4.7 \pm 1.8 (1.5-8.2)
Preoperative T stage, n (%)	cTx 6 (9.4)
	cT2 6 (9.4)
	cT3 47 (73.4)
	cT4a 5 (7.8)
Preoperative N stage, n (%)	cN+ 48 (75)
	cN - 13 (20.3)
	Not assessed 3 (4.7)
Preoperative M stage, n (%)	M0 62 (96.8)
	M1 2 (3.2)
Neoadjuvant therapy, n (%)	Chemoradiation 23 (35.9)
	Chemotherapy 1 (1.6)
	Radiation therapy 26 (40.6)

Table 1. Characteristics of patients. SD, standard deviation; ASA, American Society of Anesthesiologists; MRI, magnetic resonance imaging; T, tumor; N, node; M, Metastasis

	Male (n = 43)	Female (n = 21)	p-value
BMI (kg/m ²)	19.6 \pm 2.4 (16.0-24.7)	20.9 \pm 1.8 (18.8-27)	0.63
Anteroposterior diameter of the pelvic inlet, mm	10.81 \pm 2.15 (9.56-11.75)	11.32 \pm 1.36 (10.15-12.74)	0.04
Transverse diameter of the pelvic inlet, mm	11.69 \pm 2.02 (11.12-12.56)	12.21 \pm 2.33 (11.28-12.48)	0.03
Anteroposterior diameter of the pelvic outlet, mm	9.49 \pm 1.67 (8.71-10.31)	10.23 \pm 1.32 (9.01-10.93)	0.05
Transverse diameter of the pelvic outlet, mm	10.12 \pm 1.85 (9.67-10.68)	10.43 \pm 1.45 (9.87-11.08)	0.06
Pelvic depth, mm	12.36 \pm 2.03 (11.76-14.17)	11.73 \pm 1.12 (10.72-13.21)	0.34

Table 2. BMI and pelvic anatomical characteristics BMI, body mass index.

Characteristic	Data (n = 64)	Clavien-Dindo classification	
Laparoscopic procedures, n (%)	64 (100)		
Internal sphincteric resection (ISR), n (%)	Total ISR	18 (28.12)	
	Subtotal ISR	6 (9.37)	
Ileostomy, n (%)	35 (54.7)		
Anastomosis, n (%)	Hand sewn	51 (79.7)	
	Stapled	13 (20.3)	
Operative time, min, mean ± SD (range)	145.7 ± 22.6 (100–225)		
Estimated blood loss, ml, mean ± SD (range)	73.4 ± 39.2 (30–225)		
Specimen extraction site, n (%) (Transanal)	64 (100)		
Intra-operative morbidity, n (%)	Bleeding	1 (1.6)	
	Rectal perforation	1 (1.6)	
	Urinary retention	8 (12.5)	I
	Bowel obstruction	2 (3.2)	II
Postoperative complications, n (%)	Anastomotic leakage and stenosis	1 (1.6)	IIIb
	Anastomotic leakage	2 (3.2)	IIIa
	Rectovaginal fistula	1 (1.6)	IIIb
	Anastomotic bleeding	1 (1.6)	I
Reoperation, n (%)	3 (4.8)		

Table 3. Perioperative data in patients undergoing transanal total mesorectal excision

who did not receive an ileostomy; among patients with an ileostomy, sphincter function was assessed after the closure of the ileostomy. As shown in Table 6, the sphincter muscles recovered in most patients by six to nine months postoperatively (Kirwan I, II, and III). One patient was classified as Kirwan V and required a colostomy. Time, months According to the Kirwan’s classification, n (%).

5. DISCUSSION

According to the COLOR II trial, the most common cause associated with conventional TME failure was a narrow pelvis. Surgery becomes even more difficult when the tumor is larger than 4 cm in size and is located in the lower part of the rectum. Tumors, such as the pelvic closure, can make a clear visualization of the anatomical layer difficult when using a camera, which represents the primary cause of incomplete mesorectal excision (2). In these cases, the use of a stapler can be difficult, especially through a 12 mm trocar, which is often placed at the right iliac fossa in the horizontal position of the pelvis and perpendicular to the axis of the rectum, to obtain a sufficiently safe distance. Even when multiple 40- to 60-mm staplers are used, the cut lines are often diagonal and unable to approach the pelvic floor, which limits the rate of sphincter conservation. Although most studies have shown that women’s hips are larger than those in men (5, 6) and the TaTME surgery is recommended for men only, we found that only the transverse diameter of the pelvic outlet had any real impact on the success of TME surgery. Our study found no significant difference between the transverse diameter

of the pelvic outlet between men and women (10.12 ± 1.85 and 10.43 ± 1.45, respectively, p = 0.06), and a similar result was found for the pelvic depth measurement (12.36 ± 2.03 in men and 11.73 ± 1.12 in women, p = 0.34). These results are similar to those reported in previous Asian anatomical characteristics studies, performed by Orgiso (5) and Zhou (6), and indicated that in Vietnamese individuals, in particular, and Asian individuals, in general, TaTME surgery should be performed for female patients when the tumors in the lower rectum are larger than 4 cm in size. In our study, the percentage of female patients was 32.8%.

Epidemiological research has shown that most Vietnamese and Asian people have an average BMI (18–23 kg/m²)(13). The patients in our study had a mean BMI of 19.6 ± 2.4 kg/m², in men, and 20.9 ± 1.8 kg/m², in women, and the highest BMI among our cohort was 27 kg/m². Although the international consensus now indicates no BMI limitations that would indicate the use of TaTME over TME techniques by open, laparoscopic, or robotic surgery, (14), patients with a BMI > 30 kg/m² in Vietnam and Asia are rare. The manipulation of the correct anatomical layer can completely overcome the difficulties associated with overweight and obese patients; Therefore, the inclusion of BMI as an indication criterion for the application of TaTME surgery may not be necessary for Vietnamese and Asian populations.

Characteristic	Data	
Quality of mesorectum, n (%)	Grade 3: complete	53 (82.8)
	Grade 2: nearly complete	9 (14.1)
	Grade 1: incomplete	2 (3.1)
T staging	pT0	3 (4.8)
	pT1	2 (3.2)
	pT2	17 (26.6)
	T3	37 (57.7)
	T4	5 (7.8)
N staging	N0	43 (67.2)
	N1	15 (23.4)
	N2	6 (9.4)
Number of lymph nodes, mean ± SD	12.4 ± 3.37	
Tumor size, cm, mean ± SD	5.17 ± 1.62	
Distal margins, mm, mean ± SD	2.37 ± 0.75	
Positive	0	
Proximal margin, cm, mean ± SD	13.27 ± 6.94	
Positive	0	
CRM positive	3 (4.8%)	

Table 4. Histopathologic Characteristics of Surgical Specimens

A great advantage of TaTME surgery is the accurate identification of the safety cut line below the tumor, which allows a “clean-cut” to be achieved (15). Tumors in the lower third of the rectum tend to be small in size and below the T2 tumor stage, especially in cases where the tumor responds completely to preoperative radiotherapy; therefore, the exact identification of the lower edge is not possible during conventional TME, due to invisible and impalpable tumors (16). In our

Outcome		Data
Follow-up, months, mean ± SD		10.0 ± 3.9
Recurrence, n (%)	Disease-free survival	63/64 (98.4)
	Local and systemic recurrence	1 (1.6)
	Port site recurrence	0 (0)
Survival, n (%)	Alive	64 (100)
	Dead	0 (0)

Table 5. Oncologic Outcomes

Time, months	According to the Kirwan's classification, n (%)					Total
	I (very good)	II (good)	III (moderate)	IV (bad)	V (very bad)	
1 month	0	0	6 (18.2)	27 (81.8)	0	33 (100)
3 months	0	5 (8.9)	39 (69.7)	12 (21.4)	0	56 (100)
6-9 months	6 (11.1)	17 (31.5)	9 (16.7)	21 (38.9)	1 (1.6)	54 (100)
12 months	16 (30.8)	22 (42.3)	14 (26.9)	0	0	52 (100)

Table 6. Sphincter function outcomes

study, 78.12% of patients received chemoradiation therapy, short-term radiotherapy, or chemotherapy, 9.4% responded completely, based on preoperative clinical evaluations, and 4.8% of patients responded completely based on postoperative pathology (the complete loss any macroscopic image of the tumor). In 34.37% of patients with lower than T2 stage, the accurate identification of the safety cut line is impossible when conventional TME is performed. In contrast, the implementation of TaTME surgery achieved 100% clean cuts, with mean distal margins of 2.37 ± 0.75 cm. One major advantage of the transanal approach is that placement of a transanal purse-string suture below the tumor, under direct visual guidance, helps to guarantee an oncologically adequate distal margin. In addition, the purse-string and washout procedures minimize the risk of tumor spillage (15). Hevia et al. found that the distal margin was lower in the laparoscopy group than in the transanal group (1.8 ± 1.2 mm vs 2.7 ± 1.7 mm, respectively; p < 0.01) (17). A systematic review by Simillis et al. that examined TaTME found that positive distal margins were found in 0.3% of patients (4).

The same procedure can avoid the need for permanent colostomy among patients, contributing to improved quality of life (16). In contrast with the laparoscopic anterior resection procedure, the lower the tumor site, the more convenient the TaTME surgery is to perform. TaTME facilitates sphincter preservation, which is no longer dependent on the tumor location. In our study, the average distance from the lower edge of the tumor to the average anal margin was 4.7 ± 1.8 cm. The group with lower-third tumors included 26 patients (40.6%). For tumors in this position, previously published studies in Vietnam and other countries have reported that the rate of sphincter preservation during laparoscopic anterior resection is less than 60% (18).

Several factors could affect the surgical duration time, such as the surgeon's experience, the patient's BMI, and the number of surgical teams. In some centers, TaTME is performed by two teams simultaneously, for the 2 separate stages, the abdominal stage and the perineal stage. With currently available equipment and manpower, we

deploy one team for the whole procedure. The average surgical time in our study was 145.7 ± 22.6 minutes, which is similar to the results reported by Lacy of 166 ± 57 minutes (15) and shorter than the times reported in other studies (19).

TaTME surgery is conducted in a narrow surgical space, as a limited operation. However, when using surgical tools, such as unipolar and ultrasonic devices, the smoke released in the operating field can obstruct the view. Therefore, using the right pressure to manipulate these devices is extremely important. Several studies have reported that using the Airseal system while maintaining constant air pressure in the operating field can make it easier for the surgeon (20). Because we do not have an Airseal system, we only use an ultrasonic scalpel, and a conventional air pump system sets the pressure at 8 mmHg and the airflow at a rate of 3 liters/minute. This is a sufficient speed at which to maintain pressure, as a faster speed can make the operating field swell and become unstable, whereas a slower speed will allow the operating theater to collapse. A pressure of 8 mmHg will produce a dissection effect of the gas. However, gas buildup in the peritoneum layer was noted in 10 cases, which alters the anatomy of the mesenteric artery when dissecting in the abdominal phase.

The quality of the TME and the circumferential margins of the specimen, especially the CRM, can influence the local recurrence rate. Quirke et al. showed that the achieved plane of surgery was strongly associated with local recurrence, with a 3-year local recurrence rate of 4% at the mesorectal plane, 7% at the intramesorectal plane, and 13% at the muscularis propria plane (p = 0.0039) (21). Moreover, CRM-negative patients showed a 4% versus 12% local recurrence rate for the mesorectal and muscularis propria planes, respectively [hazard ratio (HR): 0.33, 95% confidence interval (CI): 0.15–0.74]. Xu et al. recently reported a significant improvement in the quality of the TME specimen following TaTME, with 90.5% of patients experiencing a complete TME, compared with 70.7% who underwent the classical approach of transabdominal TME (p = 0.008) (20). In our results, the mesorectum was a complete resection in 82.8% of cases and a nearly complete resection was achieved in 14.1% of cases. These data agree with the report by Buchs et al. (97.5%) (22). Our CRM positivity rate was 4.8%, which was similar to that reported by Burke et al. (4%) (23), lower than that in the study by Lacy (6.4%) (15), and higher than that reported by Buchs et al. (2.5%) (22).

In the present study, this new approach led to an intraoperative complication rate of 3.2%, including one case of a rectal perforation (a male patient, associated with a T4a tumor, with a size of 5.1 cm, a distance from the anal verge of 4.6 cm, and a BMI of 18.8 kg/m²). For this case, we immediately performed a hole closure, washed out the operating area with an iodine solution, and covered the rectum with a plastic bag. Another study examining the TaTME procedure reported an intraoperative complication rate of < 1% (24). Population-based reports

from Norway have shown a 3-fold increase in perforation rates after abdominoperineal excision compared with anterior resection (14%–15% vs 3%–4%). Perforation is a significant risk factor for adverse outcomes with regards to local control and survival rate (25). Our postoperative complication rate was 23.4%, and major complications were identified in four patients (Clavien-Dindo IIIa, IIIb), including anastomotic leakage in 3.2% of patients, rectovaginal fistula in 1.6% of patients, and combined anastomotic stenosis with leakage in 1.6% of patients. After analyzing data from 66 registered units in 23 countries, Penna and colleagues (26) reported that the anastomosis leakage rate was 6.3%. Postoperative morbidity rates in other studies have ranged from 34.2% (15) to 32.6% (2). In our study, no conversions or mortality were recorded.

Our mean follow-up time was 10.0 ± 3.9 months, and no patients were lost to follow-up. Two patients had synchronous liver metastasis, preoperatively, and among these 64 patients, we observed one patient (1.8%), who experienced a rectal perforation and developed local and distant recurrence (at 6-month follow-up). The disease-free survival and overall survival rates were 98.2% and 100%, respectively, at the end of follow-up.

The anorectal function was evaluated (Table 6), demonstrating that the sphincter muscles recovered in most patients by six to nine months postoperatively (Kirwan I, Kirwan II, and Kirwan III rates were 11.1%, 31.5%, and 16.7%, respectively). Zhang's study (27) demonstrated that the quality of life of patients six months after operations, as assessed by physical and mental health status scores, were not significantly different compared with the general population. External anal sphincter thickness decreased, from 3.7 ± 0.6 mm preoperatively to 3.5 ± 0.3 mm ($p = 0.510$) after three months, and then increased to 3.6 ± 0.4 mm ($p = 0.123$) six months after the operation. Tuech et al. found that the postoperative function was good, with all patients continent for both solid and liquid stools (28). However, prolonged anal dilatation with a 4-cm diameter rectoscope may lead to sphincter function problems. In our study, 8 patients (12.5%) appeared to suffer from postoperative urinary retention (Clavien-Dindo II). Three patients did not require urethral catheterization, and the five remaining patients were treated by temporary urethral catheterization. These symptoms discharged after 1 month. In a study by Tuech et al., five patients (8.9%) developed postoperative urinary retention, all of whom were treated by temporary urethral catheterization, with effective outcomes after 3 months (28).

Our study was conducted on a fairly large number of patients, who were operated on by a group of experienced surgeons, at a single center. Therefore, we were able to perform close and continuous follow-up. Our study has several clear limitations. First, the monitoring time was not long; therefore, parameters such as the postoperative death rate and recurrence rate after surgery may not reflect the actual situation in the long-term. Second, a randomized, controlled trial remains necessary to compare the results of laparoscopic TME

with TaTME. We are currently conducting this study, to more accurately assess the effectiveness of TaTME surgery.

6. CONCLUSION

TaTME surgery is a suitable and safe procedure that can be performed in Vietnamese patients who have a narrow and deep pelvis, even with advanced rectal tumors in the middle and lower thirds of the rectum.

- **Ethical approval and Declaration of patient consent:** The study was approved by the Ethics Committee of 108 Military Central Hospital (Ref: 786/QĐ-BV, dated 08 March 2018). Every patient signed an informed consent form before inclusion in the study.
- **Author's contribution:** Nguyen Anh Tuan and Nguyen Minh Duc contributed equally to this article. Nguyen Minh Duc and Pham Van Hiep gave a substantial contribution to the acquisition, analysis, and data interpretation. Each author had a part in preparing the article for drafting and revising it critically for important intellectual content. Each author gave final approval of the version to be published and agreed to be accountable for all aspects of the work in ensuring that questions related to the accuracy or integrity of any part of the work are appropriately investigated and resolved.
- **Conflicts of interest:** There are no conflicts of interest to declare.
- **Financial support and sponsorship:** Nil.

REFERENCES

1. Rawla P, Sunkara T, Barsouk A. Epidemiology of colorectal cancer: Incidence, mortality, survival, and risk factors. *Prz Gastroenterol.* 2019; 14(2): 89-103.
2. Van der Pas MH, Haglind E, Cuesta MA, et al. Laparoscopic versus open surgery for rectal cancer (COLOR II): short-term outcomes of a randomised, phase 3 trial. *Lancet Oncol.* 2013; 14(3): 210-218.
3. Sylla P, Bordeianou LG, Berger D, et al. A pilot study of natural orifice transanal endoscopic total mesorectal excision with laparoscopic assistance for rectal cancer. *Surg Endosc.* 2013; 27(9): 3396-3405.
4. Simillis C, Hompes R, Penna M, et al. A systematic review of transanal total mesorectal excision: is this the future of rectal cancer surgery?. *Colorectal Dis.* 2016; 18(1): 19-36.
5. Ogiso S, Yamaguchi T, Hata H, et al. Evaluation of factors affecting the difficulty of laparoscopic anterior resection for rectal cancer: "narrow pelvis" is not a contraindication. *Surg Endosc.* 2011; 25(6): 1907-1912.
6. Zhou XC, Su M, Hu KQ, et al. CT pelvimetry and clinicopathological parameters in evaluation of the technical difficulties in performing open rectal surgery for mid-low rectal cancer. *Oncol Lett.* 2016; 11(1): 31-38.
7. Tuan NT, Tuong PD, Popkin B. Body mass index (BMI) dynamics in Vietnam. *Eur J Clin Nutr.* 2008; 62(1): 78-86.
8. Edge SB, Compton CC. The American Joint Committee on Cancer: the 7th edition of the AJCC cancer staging manual and the future of TNM. *Ann Surg Oncol.* 2010; 17(6): 1471-1474.
9. Dindo D, Demartines N, Clavien P-A. Classification of surgical complications: a new proposal with evaluation in a cohort of 6336 patients and results of a survey. *Ann Surg.* 2004; 240(2): 205-213.
10. Rahbari NN, Weitz J, Hohenberger W, et al. Definition and

- grading of anastomotic leakage following anterior resection of the rectum: a proposal by the International Study Group of Rectal Cancer. *Surgery*. 2010; 147(3): 339-351.
11. Quirke P, West N, Nagtegaal I. EURECCA consensus conference highlights about colorectal cancer clinical management: the pathologists expert review. *Virchows Arch*. 2014; 464(2): 129-134.
 12. Kirwan WO, Turnbull RB, Fazio VW, Weakley FL. Pull-through operation with delayed anastomosis for rectal cancer. *Br J Surg*. 1978; 65(10): 695-698.
 13. Kim HS, Kim NK. Transanal total mesorectal excision: current East Asian perspectives for the future. *Mini-invasive Surg*. 2019; 3: 33.
 14. Adamina M, Buchs NC, Penna M, Hompes R. St. Gallen consensus on safe implementation of transanal total mesorectal excision. *Surg Endosc*. 2018; 32(3): 1091-1103.
 15. Lacy AM, Tasende MM, Delgado S, et al. Transanal total mesorectal excision for rectal cancer: outcomes after 140 patients. *J Am Coll Surg*. 2015; 221(2): 415-423.
 16. Hol JC, van Oostendorp SE, Tuynman JB, Sietses C. Long-term oncological results after transanal total mesorectal excision for rectal carcinoma. *Tech Coloproctol*. 2019; 23(9): 903-911.
 17. Trépanier J-S, Fernandez-Hevia M, Lacy AM. Transanal total mesorectal excision: surgical technique description and outcomes. *Minim Invasive Ther Allied Technol*. 2016; 25(5): 234-240.
 18. Targarona EM, Balague C, Pernas JC, et al. Can we predict immediate outcome after laparoscopic rectal surgery? Multivariate analysis of clinical, anatomic, and pathologic features after 3-dimensional reconstruction of the pelvic anatomy. *Ann Surg*. 2008; 247(4): 642-649.
 19. Kang S-B, Park JW, Jeong S-Y, et al. Open versus laparoscopic surgery for mid or low rectal cancer after neoadjuvant chemoradiotherapy (COREAN trial): short-term outcomes of an open-label randomised controlled trial. *Lancet Oncol*. 2010; 11(7): 637-645.
 20. Xu C, Song H-Y, Han S-L, et al. Simple instruments facilitating achievement of transanal total mesorectal excision in male patients. *World J Gastroenterol*. 2017; 23(31): 5798-5808.
 21. Quirke P, Steele R, Monson J, et al. Effect of the plane of surgery achieved on local recurrence in patients with operable rectal cancer: a prospective study using data from the MRC CR07 and NCIC-CTG CO16 randomised clinical trial. *Lancet*. 2009; 373(9666): 821-828.
 22. Buchs NC, Wynn G, Austin R, et al. A two-centre experience of transanal total mesorectal excision. *Colorectal Dis*. 2016; 18(12): 1154-1161.
 23. Burke J, Martin-Perez B, Khan A, et al. Transanal total mesorectal excision for rectal cancer: early outcomes in 50 consecutive patients. *Colorectal Dis*. 2016; 18(6): 570-577.
 24. Heald R. A new solution to some old problems: transanal TME. *Tech Coloproctol*; 2013; 17: 257-258.
 25. Eriksen M, Wibe A, Syse A, et al. Inadvertent perforation during rectal cancer resection in Norway. *Br J Surg*. 2004; 91(2): 210-216.
 26. Wolthuis AM. Transanal total mesorectal excision international registry results of the first 720 cases. *Ann Surg*. 2017; 266: 111-117.
 27. Zhang H-W, Han X-D, Wang Y, et al. Anorectal functional outcome after repeated transanal endoscopic microsurgery. *World J Gastroenterol*. 2012; 18(40): 5807-5811.
 28. Tuech J-J, Karoui M, Lelong B, et al. A step toward NOTES total mesorectal excision for rectal cancer: endoscopic transanal proctectomy. *Ann Surg*. 2015; 261(2): 228-233.