



## Retrospective study of teat surgical affections in dairy farms of armed forces and their treatment

Samir R.Nouh, Ahmed S.Korittum, Mahmoud H. Elkammar, Wael M. Barakat

Department of Surgery, Faculty of veterinary medicine, Alexandria University, Egypt

### Key words:

Biochemical  
Changes;  
Clinical,  
ELISA; PCR,  
Theileriosis;  
Water Buffalo

### ABSTRACT:

A survey study was done during the period between September 2010 and December 2012 on 2580 Friesian cows and heifers distributed in four armed forces farms. This work revealed that, teat wounds represent the higher acquired teat affections (28.16 %) while teat papilloma represents the lowest affection (1.65 %). The supernumerary teat represents the higher congenital teat abnormalities (36.8 %) while the lower was incompetent teat (1.5 %). The present study revealed that the prevalence of acquired teat affections were in November, December, January, and February, whenever the weather is cold and rainy and stables are muddy and the accidental injuries during milking, feeding or even laying were predominant and predictable.

**Corresponding Author:** Wael M. Barakat, [waelbarakat968@yahoo.com](mailto:waelbarakat968@yahoo.com)

### 1. INTRODUCTION

The udder and teat affections always lead to economic loss in milk yield, loss in antibiotic-treated milk, possible loss of quarter if there is a necessary to dry off, and finally reflected on the economic value of dairy animal. Hence, a better knowledge on udder and teat surgical affections and abnormalities is found to be highly needed (Schukken, et al, 1992).

The present demand for high milk production exposes the teat of dairy cattle to vigorous manipulation and high risk of injuries. Injuries to the teat can be caused by various factors including trauma; infection, husbandry practices and environmental factors (Ghamsari, et al, 1995).

The treatment of teat problems in many countries may be uneconomic thus early culling of cows with teat problems which fail to respond to simple management may be more economic but in developing world with small herds the individual cow remains a

valuable resource and the owner demanded maximum care and attention to teat conditions. (David, et al, 2005).

The purpose of this study aimed to throw a light on the most surgical affections and abnormalities of the teat in some armed forces dairy farms and to emphasis on incidence, causes, and evaluation of different methods of treatment.

### 2. MATERIALS AND METHODS

The present retrospective study was performed in the period between September 2010 to December 2012. 2580 Friesian cows and heifers were examined in four dairy farms distributed in four governments in north Egypt (Table 1).

**Table (1)** Distributions of selected dairy farms for acquired and congenital teat affections.

Farm	Government	Total cows No. in farm	of cows with teat surgical affection	
			congenital	acquired
Amriya	Alexandria	680	55	66
Nubariya	Beheira	620	64	53
ShobraShehab	Kaliobia	720	37	89
Tal El-kabeer	Ismaelia	560	48	94
Total No.	4	2580	204	302

The teat and udder were inspected for detection of any abnormalities, variation in the size or shape, inflammatory signs; presence of any lesions or congenital anomalies, milk character, its flow and the condition of supramammary lymph nodes. The suspected affected teats were externally palpated and sterile metal syphone was inserted into the teat for detection of any stenosis or obstruction and its site.

The affected animal was restrained in lateral recumbency: Light tranquilization if necessary, using 2% XylazineHcl(Xylaject, Adwia Co.) 0.1ml /kg I/M. Ring block infiltration analgesia with 10 ml 2% Lidocain hydrochloride ( Elnasr Co.). In case of teat obstruction, intramammary infusion of lidocaine HCL 2% was used during correction of the condition. Elastic tourniquet was placed around the base of the teat to provide hemostasis during surgery. Deep recent teat wounds were sutured after cleansing, irrigation and debridement, and then insert continues suture into muscle layer with cat gut, and suture the skin with simple interrupted by non absorbable suture material, then cover the wound. Then local antibiotics applied (Bivetracin spray) only to skin suture line.

Open teat surgery was indicated in teat obstruction for dissection and removing the obstructive fibrous mass or large teat lumen granuloma "pea" which fails to be withdrawn

through the teat orifice as well as teat fistula.The submucosa and intermediate layer are apposed separately with a continuous horizontal mattress suture that does not perforate the mucosa using 4-0 monofilament synthetic resorbable material (polydioxanone). The skin was closed with simple interrupted sutures by using Silk 3-0. Infusion of intramammary antibiotic (Trexine) for 3 days and application of Gentamycine ointment on wound line daily. Pen- strept L.A. were injected intramuscular every 48h for a week and I/M injection of Buta-fenil for 3 days.

**Partial teat amputation** was performed for discarding the injured portion of the teat. In case of crushed or macerated teat which had irreversible effects in teat tip according to (David, et. al., 2005). **Complete teat amputation** was necessary in the following cases: Chronic purulent or gangrenous mastitis to providing an adequate drainage, destructive old wound which involve majority of teat body, teat gangrene and accessory teat that interferes with milking process. The Technique was carried according to David, et al (2005), the affected cow was tranquilized, ring block anaesthesia at teat base and an elliptical incision around the base of the affected or extra teat. The accessory teat cistern was opened with the main teat cistern by teat probe. Then closing

of the wound by simple interrupted suture with non absorbable material.

### 3. RESULTS

From the examined animals, 19.61% were affected with different teat disorders (506 from 2580). From the affected cases, 59.68% were acquired and 40.32% were congenital abnormalities.

#### ACQUIRED TEAT AFFECTIONS:

##### 1-Teat injuries:

The teat injuries incidences represent (28.16 %) and was of a higher incidence in right hind quarters (10.60 %), followed by left hind quarters (8.27 %) but in the left forequarter about (5.30 %) and in right forequarter (3.98 %).

Better prognosis was depended on several factors: fresh better than chronic, vertical lacerations better than horizontal, proximal better than distal, sharp better than crushing, while the involvement of the teat cistern and sphincter makes the prognosis worse because teat orifice may become enlarged or stenotic. Teat injuries were classified to: superficial and deep injuries.

##### Superficial injuries

###### a- Teat ulcers

Most of teat ulcers met within this study were in lactating cows as a sequence of foot and mouth disease. The lesions may be restricted at the teat barrel (Fig. 1) or the lesions were varied from superficial ulcers (Fig. 2, a) to deep teat fissures (Fig. 2, b) which were observed during the course of foot and mouth disease.

###### b - Incised teat wound

Out of 85 cases of teat injures, 11 cases of incised wounds due to accidental injuries by sharp objects were recorded in this work (Fig.3). The longitudinal incised wound has a good prognosis than transverse one. The incised wounds was adapted suturing after cleaning, irrigation and debridement using

simple or interrupted horizontal mattress sutures (Fig.4).

##### Deep injures

During this work we met 34 cases of mashed or lacerated wounds(non perforating) with reversible changes of teat body, 29 cases respond to treatment successfully.Wound lips were adapted and sutured with symptomatic. Five cases were of irreversible teat damage; three cases were not responded to treatment and were slaughter. While two cases with irreversible damage in the teat end (Fig. 5), the affected teats were severed at the middle, and special care were given to these cases, to return again to normal functioning teat, and healing was occurred within 4 weeks and new weak sphincter was formed at the new teat end, but not quite enough to keep milk for long time. When milk escapes from the sphincter, the cow was treated as free milker.

##### 2-Teat lumen granuloma (polyps):

The teat lumen granuloma incidences (13.58 %) and was of higher incidence in right hind quarters (4.63%), followed by left hind quarters (4.30 %) but in the left forequarter (1.98 %) and in right forequarter (2.64 %).

Removal of the lumen granuloma via teat tumor extractor, teat bistoury and application of teat siphon to facilitate milking with local infusion of -chemotrypsin in teat canal to avoid fibrosis and prevent formation of further fibrotic points. Treatment was succeeded in 56% (23 cases out of 41) only while 44% were failed and resulted in quarter fibrosis.

##### 3-Teat spider

The teat spider incidences about 12.59 % (38 cases of 302) and was of higher incidence in left hind quarters (4.97%), followed by right hind quarters (3.80%) but in the left forequarter (1.65%) and in right forequarter (1.98%).

#### 4- Teat end lesions

In this study, the teat lesions incidences 10.93 % (33 cases of 302) and of higher incidence in left hind quarters (3.32%), followed by right hind quarters (2.65 %) but in the left forequarter about (2.65 %) and in right forequarter (2.31 %). Keratin corns were noticed in winter months (Fig. 6). They appear as raised, pale, swelling around the teat sphincter with small fragments of dry, keratinized material. In advanced cases, severe keratinization occurred. These corns were gently separated from the teat itself after several days of soaking in Saline, or dilute antiseptic solution to soften keratin corns that allowed subsequent removal with application of anti-inflammatory cream as Kenacomb (Smithkline Beecham Egypt).

During this work, black spot was noticed as a necrotic dermatitis around the teat sphincter. Black spots were treated by gentle removal of scabs after softening with mild antiseptic solution, application of cream, intramammary antibiotic for three days, with application of teat bougiesto prevent further stenosis by scabs (Fig. 7). During this study, teat cracks were treated by drying of the affected teats after milking then topical application of udder past (10g oxy tetracycline+10 g tannic acid+ 80g glycerin) after each milking. Recovery was observed within 4-10 days according to severity of the case.

#### 5-Enlarged teat orifice(free milker)

The enlarged teat orifice incidences 9.60 % (29 cases of 302) mainly due to direct trauma on the teat or deep wound that affect sphincter function, Higher incidence appeared in right hind quarters (2.98), followed by left hind quarters (2.65 %) but in the left forequarter about (2.31 %) and in right forequarter (1.66 %). Free milker result from weakness in the efficiency of teat sphincter of keeping the milk, resulting in continuous milk dripping (Fig. 8, b).

Treatment based on injection of minute amount of lugol's iodine with Insulin syringe around teat orifice (3-4\0.1 ml) to stimulate formation of circular rings which make the orifice narrower and stop leaking of milk. If the milk leaking still, the procedures were repeated, 21 cases of treated cases recovered, while the other 8 cases did not respond and were culled from the herd.

#### 6-Contracted sphincter (hard milker)

The contracted sphincter incidences 9.27 % (28 cases of 302) and it of a higher incidence in right hind quarters (3.32 %), followed by left hind quarters (2.65 %) but in the left forequarter about (1.65 %) and in right forequarter (1.66 %).

In hard milker, the teat orifice was narrower than normal as result of external trauma on the teat end, trauma from excessive milking machine vacuum or due to excessive narrowing in treated cases of free milker. It was noticed that, the amount of milk drained from the affected quarter were decreased and time of milking increased.

The treatment depend on widening of sphincter through cutting of sphincter by teat slitter and a milk tube is applied for a week days ,the affected teat was painted with Dexamethasone 0.2% ointment in addition to Dicloflame (UNI Pharma El Obour city, Cairo-Egypt) (1mg/50 kg) I/M for 5 days.

#### 7-Teat fistula

The teat fistula incidences about 8.27 % (25 cases of 302) and was of a higher incidence in right hind quarters (2.98%), followed by left hind quarters (2.32 %) but in the left forequarter about (1.32 %) and in right forequarter (1.66 %).

The lesion appears as an abnormal passage connecting between the teat cistern and the teat surface. The opening of the fistula discharging milk, some cases were suffering from suppurative mastitis and the abnormal opening discharging pus (Fig. 9). Cases suffering from suppurative mastitis in which

teat was swollen and painful and pus was discharged from fistulous opening, must be firstly treated from mastitis until discharge become clear and teat wall return to normal condition with distinct fistulous opening.

Correction of teat fistula was performed by excision of the fistulous tract to expose unscarred teat wall. Then the teat was closed as discussed before. Complete closure of the fistula was occurred after a month of surgery (Fig. 10).

### **8- Milk stone**

The milk stone incidence (3.97 %) and of higher incidence in right hind quarters (1.65 %), followed by left hind quarters (1.32 %) but in the left forequarter about (0.99 %) and in right forequarter (0.00 %).

In this study, several factors were sharing in formation of lactolith; mineral deposits, damage in epithelial lining teat canal and high concentrated milk. These factors were aggravated during the course of foot and mouth disease or chronic mastitis. As, the painful teat ulcers prevent complete evacuation of milk leading to reduction milk amount and increase concentration. While, streak canal inflammation resulting in damage in lining epithelium.

These cases were suffered from intermittent free movement of milk and on palpation with gentle pressure along the teat cistern and teat canal reveals presence of movable teat calculi and the obstruction becomes complete when the lactolith located at teat orifice. The small milk stone were drained with milk during hand milking, while in case of the large lactolith, 30 ml saline were infused through the orifice which was dilated by teat dilator, then massive hand milking to help in pushing of the calculi outside.

### **9 -Teat gangrene**

The teat gangrene incidences (1.98 %), the higher incidence in right hind quarters (0.99%), followed by left hind quarters (0.66 %) but in the right forequarter about (0.32 %) and in left forequarter (0.32 %).

Teat gangrene was sequelae of gangrenous mastitis. At the beginning the skin of the teat was ischemic and become dark brown in color and cold and painless (Fig. 8, a). The lesion extend from base of the teat to teat barrel and the skin color become dark red to dark bluish according to time spends. Also red ulcers were noticed (Fig. 11).

In later stage, severe loss of tissues of teat wall may occur forming an external opening of teat wall (Fig. 12). Complete amputation of affected teat was indicated in case of gangrenous mastitis to make good drainage as the best choose. In case of very mashed lacerated teat with irreversible changes, partial amputation at the beginning of healthy tissue.

### **10- Teat Fibropapilloma**

The teat papilloma incidences (1.65 %) and was higher incidence in right hind quarters (0.67 %), followed by right forequarters (0.32 %) but in the left hind quarter about and leftforequarter reached to (0.00 %). In this survey, teat fibropapilloma was noticed in large number of flat elevations at teat end resembling grain of rice flat lesions (Fig.13). Usually no treatment of rice-grain flat lesions, unless they interfere with milk process when it located at the teat end.

Single pedunculated fibropapilloma was noticed at the teat wall near the end (Fig. 14).

Snipping of these lesions were done by curved scissor and then touched with a teat mixture of tannic acid and oxytetracycline powder (1:1) for three days. When large numbers of cattle are affected, the teat evaluation after each milking and

any warts must be snipped and touched by teat mixture

**CONGENITAL TEAT ABNORMALITIES:**

The most important congenital affections in teat of examined cows included supernumerary teats (36.80 %), too closed teats (26.50 %), very short teats (23 %), bottle teat obstruction (4.90 %) and incompetent teat sphincter (1.50 %).The

high incidence was met in supernumerary teats 36.8 % of congenital teat abnormalities (75cases of 204) while the lower was incompetent teat sphincter 1.5 % of congenital teat abnormalities (3 cases of 204). On other hand no cases of congenital fistula were recorded.

**Table (2)** Incidence of acquired teat affections in four quarters

		Forequarters				Hindquarters				Total No.	
		R		L		R		L		Total No.	%
			%		%		%		%		
1	Teat injuries	12	3.98	16	5.30	32	10.60	25	8.27	85	28.16
2	Teat lumen granuloma	8	2.64	6	1.98	14	4.63	13	4.30	41	13.58
3	Teat spider	6	1.98	5	1.65	12	3.80	15	4.97	38	12.59
4	Teat end lesions	7	2.31	8	2.65	8	2.65	10	3.32	33	10.93
5	Enlarged teat orifice	5	1.66	7	2.31	9	2.98	8	2.65	29	9.60
6	Contracted sphincter	5	1.66	5	1.65	10	3.32	8	2.65	28	9.27
7	Teat fistula	5	1.66	4	1.32	9	2.98	7	2.32	25	8.27
8	Milk stone	-	-	3		5	1.65	4	1.32	12	3.97
9	Teat gangrene	1	0.32	-		3		2	0.66	6	1.98
10	Teat papilloma	2	0.66	1	0.33	2	0.67	-	-	5	1.65
	Total No	51	16.89	55	17.19	104	33.28	92	30.46	302	100

Chi<sup>2</sup> = 42.55\*\*

\*\* = Significant at (P < 0.01).

**1-Supernumerary teat**

Supernumerary teats compared 36.8 % of congenital teat abnormalities (75 cases of 204). The number of extra teats reached to 28 %, 45.34 %, 17.34 % and 9.34 % for 1, 2, 3 and 4 extra-teats. They were classified to five grads which may be functional (36%) or non functional (64%) into:

**1- Non functional supernumerary teats:**

The non-functional supermammary teats constituted about 64 % from the examined animals with 40 % and 24 % for grade I and grade II, respectively.

**a-Supernumerary teat (I)**

This condition were recorded in 30 cases. This degree of supernumerary teat characterized by an extra teat which just appears as elevation of skin surface,

presentmainly as two elevations caudal to main teats and it left without interference (Fig. 15). In grade I extra teats incidence were 0, 26.67, 8 and 5.34 % for 1, 2, 3 and 4 extra teats.

**b-Supernumerary teat (II)**

It recorded in 18 cases. This degree of supernumerary teat characterized by presence of a non functional extra teat with teat canal and sphincter which not attached to teat or gland sinus (Fig. 16, a). In grade II extra teats incidence were 2.67, 12, 5.33 and 4 %for 1, 2, 3 and 4 extra teats.

**2- Functional supernumerary teats:**

The functional supermammary teats percentage 36 % from the examined animals 20 % of Grade V and 4 % and 12 % for grade IV and III, respectively.

**a-Supernumerary teat (III)**

In this grade number of extra teats were: one extra teat (2.67 %), two extra-teats (5.34 %) and three extra-teats (4 %) from the examined teats. This condition was recorded in 9 cases. This degree of supernumerary teat characterized by presence of an extra teat with teat canal and sphincter which attached to gland sinus (Fig. 16, b) and (Fig. 17), surgical removal was done (Fig.18).

#### **b-Supernumerary teat (IV)"webbed or conjugated teat"**

During this study webbed or conjugated teat was recorded in three cases. This condition is a functional extra teat which attached to teat sinus and ranged from distinct extra teat to an elevation area on teat wall with an opening discharging milk which usually confused with teat fistula. In grade IV all examined cases were with one extra-teat constituting 4 %. Surgical removal of webbed teat in heifer was done before six months age by tight ligation by double non absorbable thread (Fig. 19) and sloughing occurred after three weeks (Fig. 20). In older ages, surgical removal was necessary when the teat interfere with milking process.

#### **c-Supernumerary teat (V)"Hypermastia"**

15 cases with a functional supernumerary teat were met. Characterized by a supernumerary teat which has teat canal, orifice, sphincter and its own quarter in addition to four normal quarters (Fig. 21). In grade V the number of one extra teats observed in (18.67 %) in examined teats and two extra teats constituted 1.34 % of examined teats.

#### **2-Too closed hind teats**

This abnormality was observed in 26.5 % of congenital teat abnormalities (54 cases of 204). The two hind teats were much closed and interfere with milking process (Fig. 22).

#### **3-Very short teats**

Very short teats were an important factor in udder problems because of teat cups of milking machine cannot be fixed on short

teat and thus the quarter not milked with machine (Fig. 23). This condition was observed in 23% of congenital teat abnormalities (47 cases of 204).

#### **4- Teat hyperplasia (bottle teat)**

We met this condition in 7.3% of congenital teat abnormalities; out of 204 we found only 15 cases with bottle teat. We observed that teat hyperplasia is a congenital condition in which, the affected teat was longer and larger than normal, and milk cup cannot be fixed on this teat, and increase the possibility of mastitis. No line of treatment except culling from breeding (Fig. 24).

#### **5-Congenital teat obstruction:**

In this study, congenital teat obstructions were met within 4.9% of congenital teat affections, (10 out of 204 cases).

#### **1- Imperforated teat**

Imperforated teat was met with only in six heifers. This condition was recorded mainly in heifers at first lactation due to congenital absence of teat orifice characterized by incomplete canalization of streak canal or complete absence of streak canal (Fig. 25). On palpation, the teat was filled with milk but when stripped by hand no milk discharged. Treatment by perforation of the membrane at the site of teat orifice by teat slit until milk appears and application of teat tube for 6-10 days. Only one heifer recovered and the other cases failed due to congenital membranous obstruction (4 cases).

#### **2- Congenital membranous obstruction**

The condition characterized by presence of a membrane prevent milk flow in first calving heifers, the milk secreted and the quarter filled with milk till the obstruction position, which may be at teat base or in mid teat or at the teat end closing the teat canal. Treatment was successful as cases of teat spider.

#### **6-Incompetant teat sphincter (relaxation of teat sphincter)**

In our study we met three heifers with incompetent teat sphincter. The milk was

dropped intermittently from teat orifice (Fig. 26). This condition respond to treatment by injection of small amount of Iugol's iodine

with Insulin syringe around teat orifice (2-3\0.1 ml), two heiferswere respond and milk leaking was stopped.

**Table (2):** Incidence of congenital teat surgical abnormalities

		Total No.	%
1	Supernumerary teats	75	36.8%
2	Too closed hind teats	54	26.5%
3	Very short teats	47	23%
4	Bottle teat (hyperplasia)	15	7.3%
5	Congenital teat obstruction	10	4.9%
6	Incompetent teat sphincter	3	1.5%
Total No.		204	

Chi<sup>2</sup> = 11.66\*\*

\*\* = Significant at (P < 0.01).

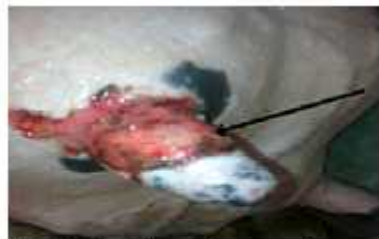

Fig. (1): teat ulcer in 7 years old cow

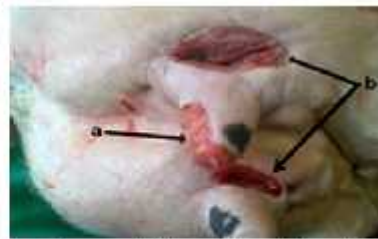

Fig. (2): superficial teat ulcer (a), and deep teat ulcer (b) in 6 years old cow

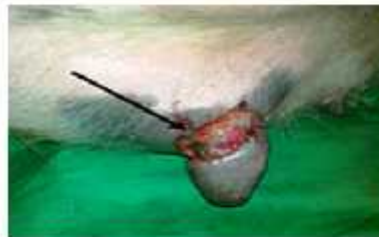

Fig. (3): incised teat wound in 6 years old cow

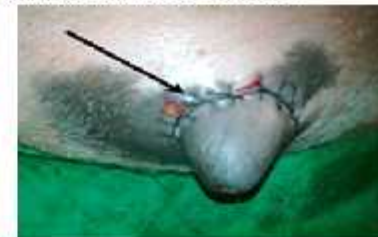

Fig. (4): the previous case after suturing

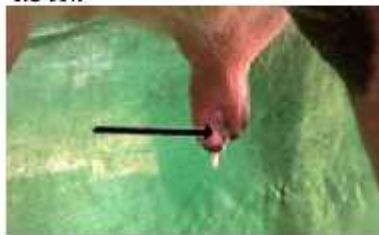

Fig. (5): old destructive wound in 6 years old cow resulting in free milker

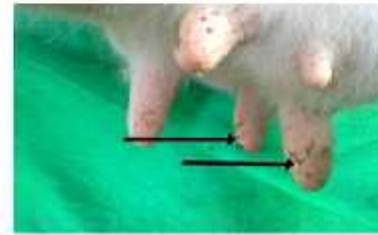


Fig. (6): showing keratinized corns in 5 years old cow

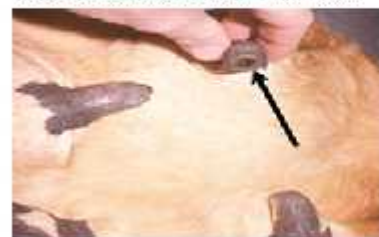

Fig. (7): black spot in 4 years cow

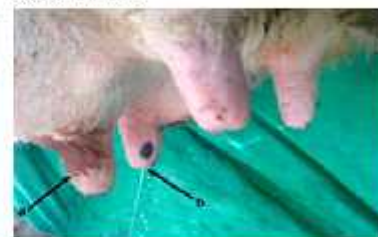

Fig. (8): (a) ischemic necrosis of one teat (b) continuous milk dripping (free milker)



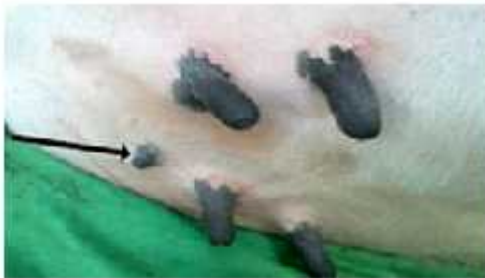

Fig. (17): an extra teat (III) in one year old heifer

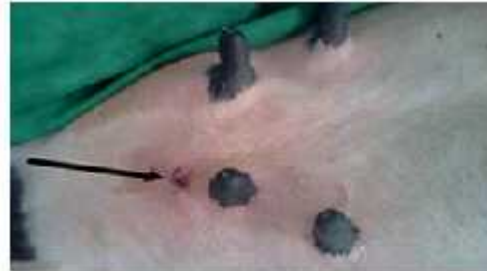

Fig. (18): showing the previous case one month after surgical removal of the extra teat

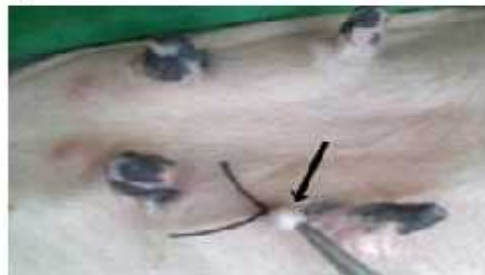

Fig. (19): webbed teat (extra teat IV) after ligation in 6 month old heifer

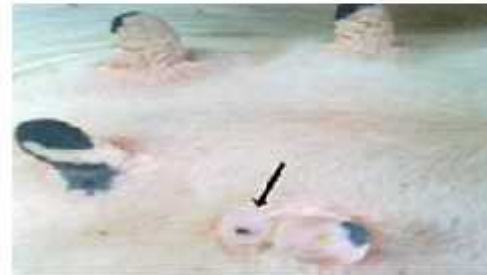


Fig. (20): the previous case after removal of webbed teat

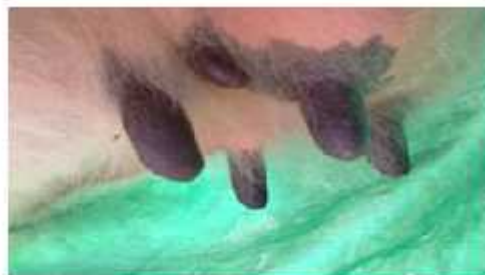

Fig. (21): extra quarter (hypermastia) in 4 years old cow

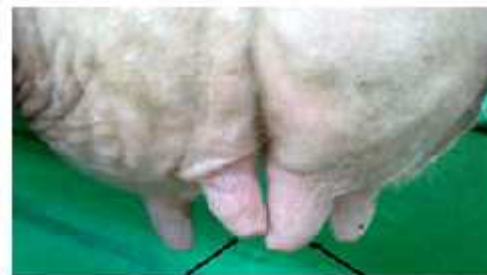

Fig. (22): closed hind teats in 5 years old cow

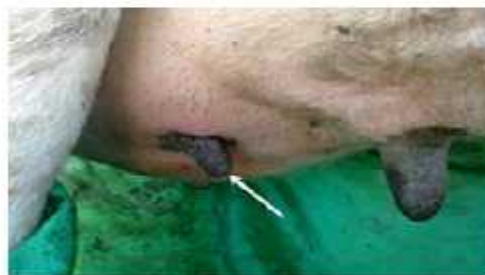

Fig. (23): very short teat in 6 years old cow

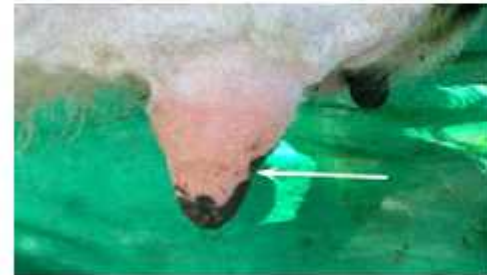

Fig (24): teat hyperplasia (bottle teat) in 7 years cow

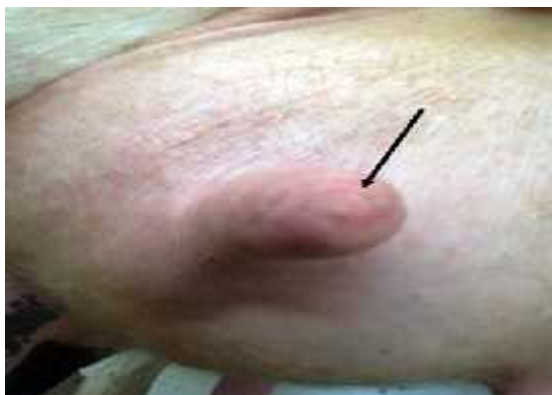

Fig. (25): Imperforated teat in 1st calving Heiferheifer



Fig. (26): Incompetent teat in 1st calving

#### 4. DISCUSSION

The study under investigation gives an attention to the prevalent teat surgical affections in imported cattle which considered the most important in diary industry all over the world and in Egypt.

The present investigation reveals that, there was a positive relationship between claw, joint affection and teat affections. This was also mentioned by Mahdy (1998) and the overcrowded cows were more exposed to other animal's bits, horns and stepping on the teats by neighboring animals resulted in teat injuries.

In agreement with Mahdy (1998), it was found that, lactating cows were highly affected with acquired affections than dry cows and heifers. These affections in lactating cows were high in 3 years old (7.4%) after first calving due to less experience heifers, then increased in cows over 7 years old (7.48%) after 5th lactation due to big and pendulous udders.

Overcrowded animals were more exposed to other animal's bits, horns and stepping on the teats by neighboring animals resulted in teat injures. This result was also mentioned by Matzke, et al, (1992) and Mahdy (1998).

In agreement with Bristol (1989), Shearer (2003), Couture and Mulon (2005) and Misk (2008), the better prognosis of teat laceration for healing and

return to function depended on several factors as: fresh better than chronic, vertical lacerations better than horizontal, proximal better than distal, sharp better than crushing. While the involvement of the teat cistern and sphincter makes the prognosis worse because teat orifice may become enlarged or stenotic.

The teat lumen granuloma were of a higher incidence in right hind teats followed by left hind teats. It was attributed to the liability for traumatization of hind teats as they are longer than the fore teats. This was in agreement with Mahdy (1998). Surgical removal of the teat lumen granuloma was operated by teat tumor extractor and application of teat siphon to facilitate milking with local infusion of -chemotrypsin in teat canal to avoid fibrosis and prevent formation of further fibrotic points. This method is the same used by Davide, et al, (2005) and Misk (2008).

Teat spiders represent membranous obstruction of teat canal or obstruction at the base of teat cistern as result of presence of obstructive tissues in the teat canal were met as acquired and congenital anomaly (Johnson, 1988 and Singh et al, 1993). When congenital, the condition is associated with improper development of the teat cistern or teat canal, whereas acquired obstructions are caused by injury, tumour or infections (theilitis, cisternitis, mastitis).

Keratin corns were noticed mainly in winter months and all teats were affected. They appear as raised, pale, swelling around the teat sphincter with small fragments of dry and keratinized material. In advanced cases severe keratinization occurred. These results are the same of that mentioned by Blowey and Weaver (1991).

This study revealed that, black spot was noticed as a necrotic dermatitis around the teat sphincter. The condition mainly occur due to environmental traumas as over milking, improper vacuum of milking machine and wet teat exposed to cold weather just after milking. The same was described with Blowey and Weaver (1991). The treatment done by gentle removal of scabs after softening with mild antiseptic solution, application of anti inflammatory cream, intramammary antibiotic for three days, with application of teat bougie to prevent further stenosis by scabs.

Teat cracks were treated by drying of the affected teats after milking then topical application of udder past (10g oxy tetracycline+10 g tannic acid+ 80g glycerin) after each milking. Recovery was observed within 4-10 days according to severity of the case. Blowey and Weaver (1991) treated this condition with iodine in glycerin (1- 4). Abd El Bary (2000) used tannic acid in glycerin (20%) while Misk (2008) used both of the previous methods.

Regarding to treatment of free milker, it was treated by injection of minute amount of lugol's iodine using insulin syringe around teat orifice (3-4\0.1 ml) to stimulate formation of circular rings which make the orifice narrower and stop leaking of milk. These results are in agreement with that of ( David, et al, 2005, Mahdy, 1998, Misk , 2008 and Thomas and Simon , 2008).

Treatment of hard milker depended on widening of sphincter through cutting of sphincter by teat slitter and a milk tube is applied for a week. The same method was mentioned by(Misk , 2008).

In agreement with Misk (2008) and Thomas and Simon (2008) the entire fistulous tract was excised and skin edges were sutured by simple interrupted suture with non absorbable suture material. Teat bougie was introduced in the teat canal and left in position till complete healing.

Complete amputation of the affected teat was indicated in case of gangrenous mastitis to make good drainage as the best choose. While in case very mashed lacerated teat with irreversible changes, partial amputation at the beginning of healthy tissue was done. These results are in agreement with Misk (2008) while Weaver (1986) used burdizzo at the junction of middle and distal third of the teat. Fibropapilloma was noticed near the teat end and was snipped by curved scissor, then touched with teat mixture of tannic acid and oxytetracycline powder (1:1) for three days. These results are in agreement with (Thomas and Simon, 2008).

In agreement with Mahdy (1998) when the extra teats interfere with milking process, the surgical interference must be done before 6 months, While in cases of functional teats in older ages, surgical removal in this work was done.

## 5. REFERENCE

- Abd El-Bary, A.A.G 2000. Surgical affections of the udder and teats in Friesian cows. M.V.Sc Thesis of Vet. Med.(surgery) Zagazig University. Banha branch.
- Blowey, R.W and Weaver, A.D 1991. A color Atlas of diseases and disorders of cattle publishing place London provider Nolfe chapter II, udder and teat disorders 177-188.
- Bristol, D. G. 1989. Teat and udder surgery in dairy cattle –part I. *Compend Contin Educ Pract Vet* 11:868-872.
- Couture, Y. and Mulon, P.Y. 2005. Procedures and surgeries of the teat. *Vet. Clin. Food anim.* March (2005), 21:173-204.
- In David, W., Adrian, S., and Guy S. J. 2005. Bovine surgery and lameness. 2nd edition. P: 158-167.

Ghamsari, S.M., Taghugi, K., Abe, N., Acorda, J.A., Sato, M. and Yamada, H. 1995. Effect of different suture patterns on wound healing of the teat in dairy cattle. *J. Vet. Med. Sci.* 57:819-824.

Johnson, L. 1988. Mammary gland. In: *Textbook of large Animal Surgery*. 2nd Ed. (ed. Oehme, F.W.) Williams and Wilkins. pp: 220-227.

Mahdy, A.E.E. 1998. Teat surgery in dairy animals. Ph.D. of Vet. Med. (surgery), Zagazig University.

Matzke, P., Holzer, A. and Denke, J. 1992. A contribution to the influence of environmental factors on the incidence of udder diseases. *Tierarztl. prax* 1992;20-32.

Misk, N.A. 2008. *Atlas of veterinary surgery* 1st edition; page:304-313.

Schukken, Y.H., Lesile, K.E., Weeersink, A.J and Martin, S.W. 1992. Ontario bulk milk somatic cell count reduction program. *J. Dairy Sci.* 75, 3352-3358.

Shearer, J.K. 2003. Non infectious lesions of the bovine teat; Folrida extention cooperative Extention Service, IFA Extention, Folirda University. DS66.

Singh, J., Singh, P. and Arnold, J.P. 1993. The mammary glands. In: *Ruminant Surgery* (eds. Tyagi, R.P.S. and Singh J.) CBS Publishers and Distributors, New Delhi, India. pp:167-174.

Thomas J. D. and Simon F. P. 2008. *Rebhun's diseases of dairy cattle* 2nd edition. pp: 327:357.

Weaver, A.D. 1986. *Teat Surgery Bovine surgery and Lameness*. pp:141-149. Blackwell Scientific Publications.