



Case Report

A Rare Case of Alkaptonuria - Achilles Tendon Rupture

Mahesh D V¹, Gunnaiah², Deepak CD¹, Vijay Chandar³

¹Assistant Professor, ²Professor & HOD, ³Post Graduate,
Dept of Orthopedics, Adhichunchanagiri Institute of Medical Sciences, B G Nagar, Karnataka, India.

Corresponding Author: Mahesh D V

Received: 08/03/2014

Revised: 02/04/2014

Accepted: 26/04/2014

ABSTRACT

INTRODUCTION - Alkaptonuria is a rare metabolic disorder affecting 1 in 250,000 to 1 million people worldwide due to an autosomal recessive mutation of homogentisate oxidase gene, located on chromosome 3q21-q23.

CASE REPORT - A 37 year old female came to the outpatient department with chief complaint of inability to move the left ankle and pain over the back of left ankle since 1 week following a trivial trauma. She was unable to walk on the affected side since injury. On Local examination revealed tenderness at tendo achilles insertion site with a gap, Thompsons test was positive. Ultrasound showed tear of achilles tendon with thickening.

DISCUSSION - Alkaptonuria is a benign, rare inherited condition affecting 1 in 250,000 to 1 million people worldwide. This disorder usually appears in early life but skeletal deformities usually occur after third decade of life.

CONCLUSION - Usually achilles tendon rupture occurs following trauma and spontaneous achilles tendon rupture is rare. Ochronotic achilles tendon tear is a rare entity and can present with spontaneous Achilles tendon tear as the initial sign. Hence in case of spontaneous achilles tendon tear one has to keep in mind the unusual diagnosis of Alkaptonuria.

KEY WORDS- Alkaptonuria, achilles tendon, autosomal recessive mutation.

INTRODUCTION

Alkaptonuria is a rare metabolic disorder affecting 1 in 250,000 to 1 million people worldwide due to an autosomal recessive mutation of homogentisate oxidase gene, located on chromosome 3q21-q23. This defect results in deficiency of homogentisate 1,2-dioxygenase and accumulation of homogentisate in fibrous and cartilaginous tissues leading to degenerative musculo-skeletal deformities in the third or fourth decade of life, excreting

homogentisic acid in the urine (homogentisic aciduria). The hallmark of the disorder is a triad of degenerative arthritis, ochronotic pigmentation and urine that turns black on alkalinization.

CASE REPORT

A 37 year old female came to the outpatient department with chief complaint of inability to move the left ankle and pain over the back of left ankle since 1 week following a trivial trauma. She was unable to

walk on the affected side since injury. On Local examination revealed tenderness at tendo achilles insertion site with a gap, Thompsons test was positive. Ultrasound showed tear of achilles tendon with thickening.

Patient was posted for tendo-achilles repair, intra-operatively around 6cm blackish discoloration of Achilles noted extending from 5cmdistal to musculo-tendinous junction up to 2 cm proximal to the insertion site. The discolored part of tendon was resected and tendon reconstruction done by bosworth technique, following which the limb was immobilized in an above knee POP cast with knee in flexion and ankle in plantar flexion. The resected portion was sent for histopathological examination. (fig 3)

A diagnosis of alkaptonuria was suspected and a retrospective history revealed patient with symptoms of multiple joints pain like knee, shoulder and back pain on and off .History of darkening of urine on standing was present.

Following test were performed

1. Urine turned dark on standing in atmospheric air for few hours (fig 5)
2. Urine Benedict's test: urine turned black on adding Benedict's reagent .then on heating slowly, a greenish yellow precipitate was formed which also turned black after few hours of standing. (fig4b)
3. Ammoniacal silver nitrate test: appearance of ring of black precipitate was observed. (fig 4a)
4. Ferric chloride test: appearance of a transient green color on addition of ferric chloride to urine sample was observed.

Xray spine shows degenerative changes with decreased disc space and end plate sclerosis, degenerated inter-vertebral discs with calcification throughout thoracic & lumbar vertebra, generalized osteopenia was seen. (fig 1a & 1b)

Echo showed-thickened mitral leaflets with Mitral valve prolapse, mitral valve stenosis and mitral valve regurgitation.

Based on fore mentioned feature a diagnosis of alkaptonuria was made.

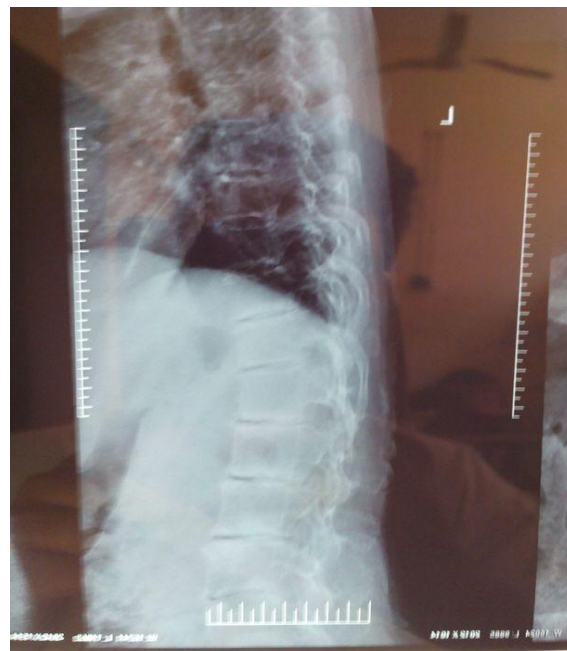

Fig:1a (LS spine LATERAL view)

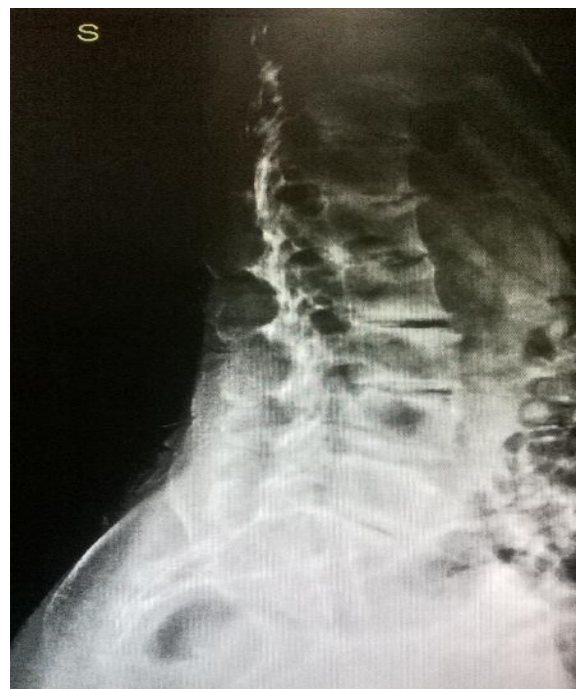

Fig:1b (LS spine LATERAL view)

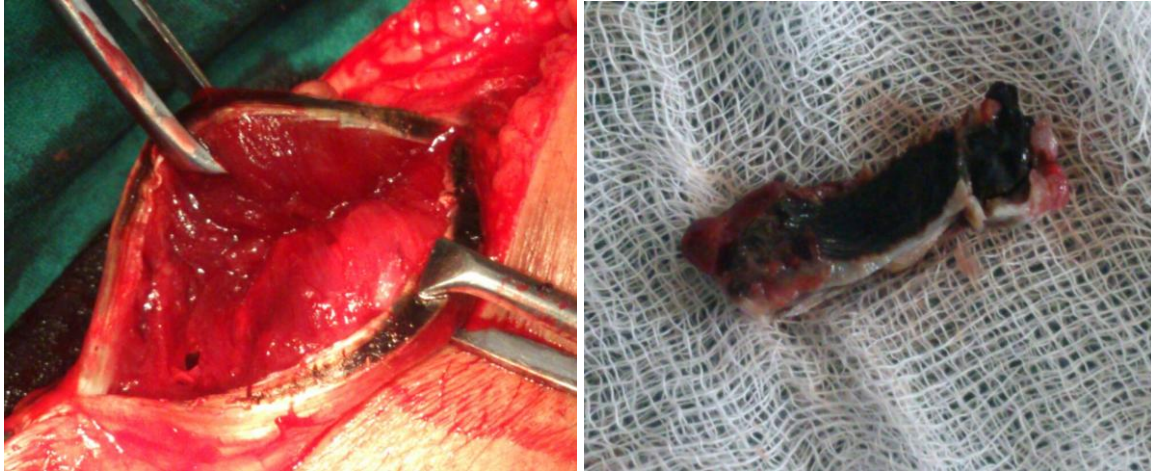

Fig: 2 & 3 (Intra-operative specimen of achilles tendon)




Fig 4a - Ammoniacal silver nitrate test.




Fig4b - Benedicts test

DISCUSSION

Alkaptonuria is a benign, rare inherited condition affecting 1 in 250,000 to 1 million people worldwide. This disorder usually appears in early life but skeletal deformities usually occur after third decade of life.

Upon contact with air, homogentisate is oxidized to form pigment like polymeric material responsible for the black color of urine. Although blood homogentisate levels are kept very low through rapid kidney clearance, over a period of time, homogentisate is deposited in cartilage throughout the body and is converted to the pigment- like polymer through an enzyme-mediated reaction that occurs chiefly in collagenous tissues. As the polymer accumulates within cartilage, a process that takes many years, the normally transparent tissues become slate blue, an effect ordinarily not seen until adulthood.


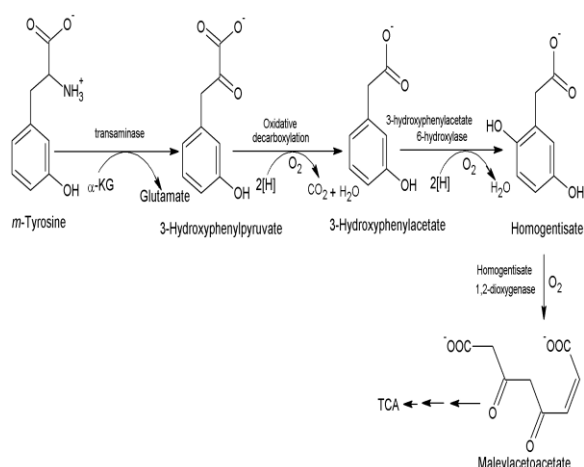


Fig: 5 (Urine turned dark on standing in atmospheric air for few hours).



The basic defect in alkaptonuria is deficient homogentisate 1,2-dioxygenase activity. Nitisinone inhibits 4-hydroxyphenylpyruvic acid dioxygenase.

The earliest sign of the disorder is the tendency for diapers to stain black. In spine Symptoms in the lumbar and thoracic spine preceded those in the cervical spine. Narrowing of the disk space was followed by disk calcification and fusion of the disk. Pigmentation of the sclera and ear cartilage occurred only after the age of 30 years and was extremely variable in severity; some had tendon-related findings with thickened Achilles tendons and muscle tears after minimal trauma. Cardiac involvement include aortic dilatation or cardiac-valve involvement i.e., aortic or mitral-valve calcification or regurgitation on echocardiography.

Urinary and plasma homogentisate levels can be quantitatively measured using spectrophotometric and chromatographic method.

Therapeutic approach include mega dose of vitamin C for the degradation of homogentisic acid. Antiresorptive drugs such as alendronate and ibandronic acid are unproven in ochronotic spine with osteopenia. The aim of treatment is to halt the gradual destruction of cartilage, arthritis,

lumbosacral ankylosis, limitation of motion, and deterioration of bone. Recently, a new drug has been identified which inhibits 4-hydroxyphenylpyruvate dioxygenase which is the enzyme that produces homogentisic acid. This drug is Nitisinone (NTBC) whose chemical name is 2-(2-nitro-4-trifluoromethylbenzoyl) 1, 3-cyclohexanedione and is sold under the brand name Orfadin. Nitisinone, at a dose of 1 mg/kg/day is safe and effective in tyrosinemia type 1 but has not yet been approved for use in alkaptonuria

CONCLUSION

Usually achilles tendon rupture occurs following trauma and spontaneous achilles tendon rupture is rare. Ochronotic achilles tendon tear is a rare entity and can present with spontaneous Achilles tendon tear as the initial sign. Hence in case of spontaneous achilles tendon tear one has to keep in mind the unusual diagnosis of Alkaptonuria.

Source of financial or other assistance – NIL

Competing Interests - The authors declare that they have no competing interests. All the authors have read and approved the final manuscript.

Consent - was taken from the institutional ethical committee.

REFERENCES

1. Garrod AE. The Croonian lectures on inborn errors of metabolism. Lecture II. Alkaptonuria. *Lancet* 1908; 2:73–9.
2. Tharini GK, Vidya R, Hema N, Parvathy D, Praveen B. Alkaptonuria. *Indian j. Dermqatol.* 2011;56:194-196.
3. Ashok KD, Syamali M, Anindya D, Tarun KG. Alkaptonuria diagnosed in a 4 month old baby girl in a case report. *Cases J.* 2008;1:308.

4. Gayathri B, Sujatha R, Sumitra G, Kavitha M, Vijaya D. A case of Alkaptonuria . International journal

of biochemistry and biotechnology. 2012;1:188.

How to cite this article: Mahesh D V, Gunnaiah, Deepak CD et. al. A rare case of alkaptonuria- achilles tendon rupture. Int J Health Sci Res. 2014;4(5):323-327.

International Journal of Health Sciences & Research (IJHSR)

Publish your work in this journal

The International Journal of Health Sciences & Research is a multidisciplinary indexed open access double-blind peer-reviewed international journal that publishes original research articles from all areas of health sciences and allied branches. This monthly journal is characterised by rapid publication of reviews, original research and case reports across all the fields of health sciences. The details of journal are available on its official website (www.ijhsr.org).

Submit your manuscript by email: editor.ijhsr@gmail.com OR editor.ijhsr@yahoo.com